



VOICE DISORDERS PRAXIS CONTENT REVIEW

National Black Association for Speech-Language and Hearing

Afua Agyapong, PhD

Speaker Disclosure

Afua Agyapong, PhD

Relevant Financial Relationships:

- Receives a fee for presenting at today's Praxis content review

Relevant Nonfinancial Relationships:

- Dr. Agyapong has no relevant nonfinancial relationships to disclose

Objectives

Upon successful completion of this review course, participants will be able to:

1. Describe the anatomy and physiology of vocal mechanism
2. Demonstrate techniques for the prevention of voice disorders through education and counseling of clients
3. Identify three types of voice disorders
4. Identify appropriate evidence-based intervention for pediatric and adult clients with voice disorders.

Review of Anatomy

- The larynx acts as a sphincter
 - Closing off to protect the lower airways from foreign material
 - Opening to aid breathing
 - Serving as the sound source for voice production as pressure from the respiratory system is transferred from the subglottal space through the glottal space into the supraglottal cavity

- Cartilages

- 3 paired
- 3 unpaired

- Muscles

- Intrinsic
- Extrinsic

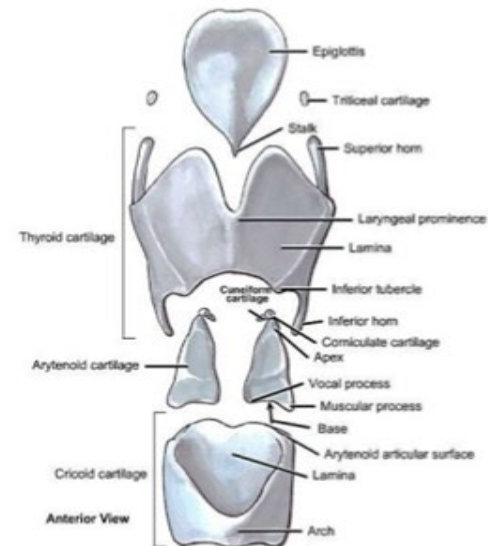
Cartilages

3 Unpaired

- Thyroid
- Cricoid
- Epiglottis

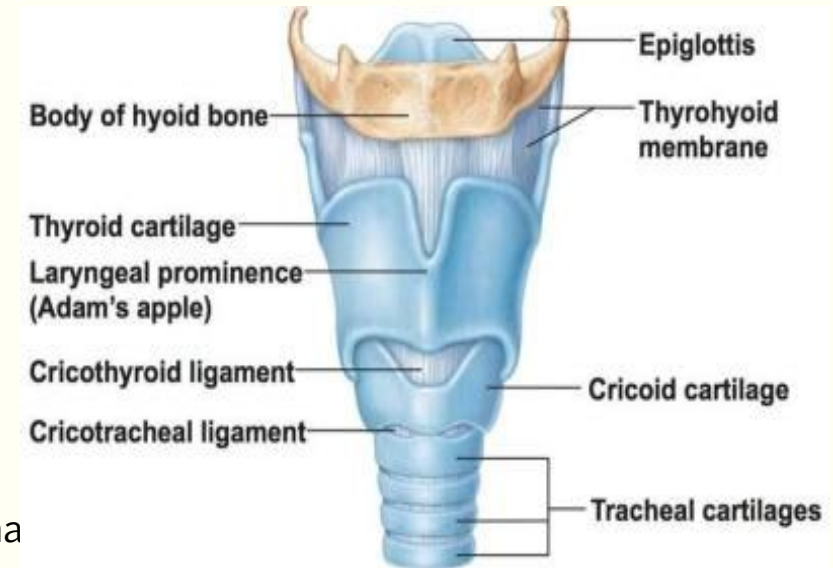
3 Paired

- Arytenoid
- Corniculate
- Cuneiform



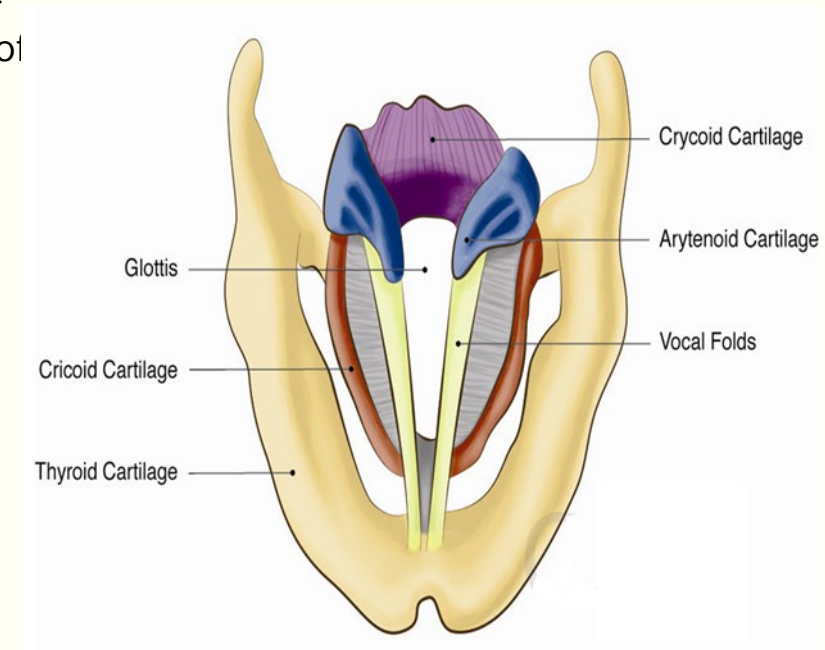
The Larynx

- Comprised of three unpaired cartilages
 - Cricoid cartilage
 - Complete ring atop the trachea
 - Side view looks like a signet ring, higher in the back
 - Articulates with thyroid via cricothyroid joint
 - Thyroid cartilage
 - Largest laryngeal cartilage
 - Articulates with cricoid cartilage via paired processes that
 - Epiglottis cartilage
 - Leaflike cartilage
 - Protective structure during swallowing



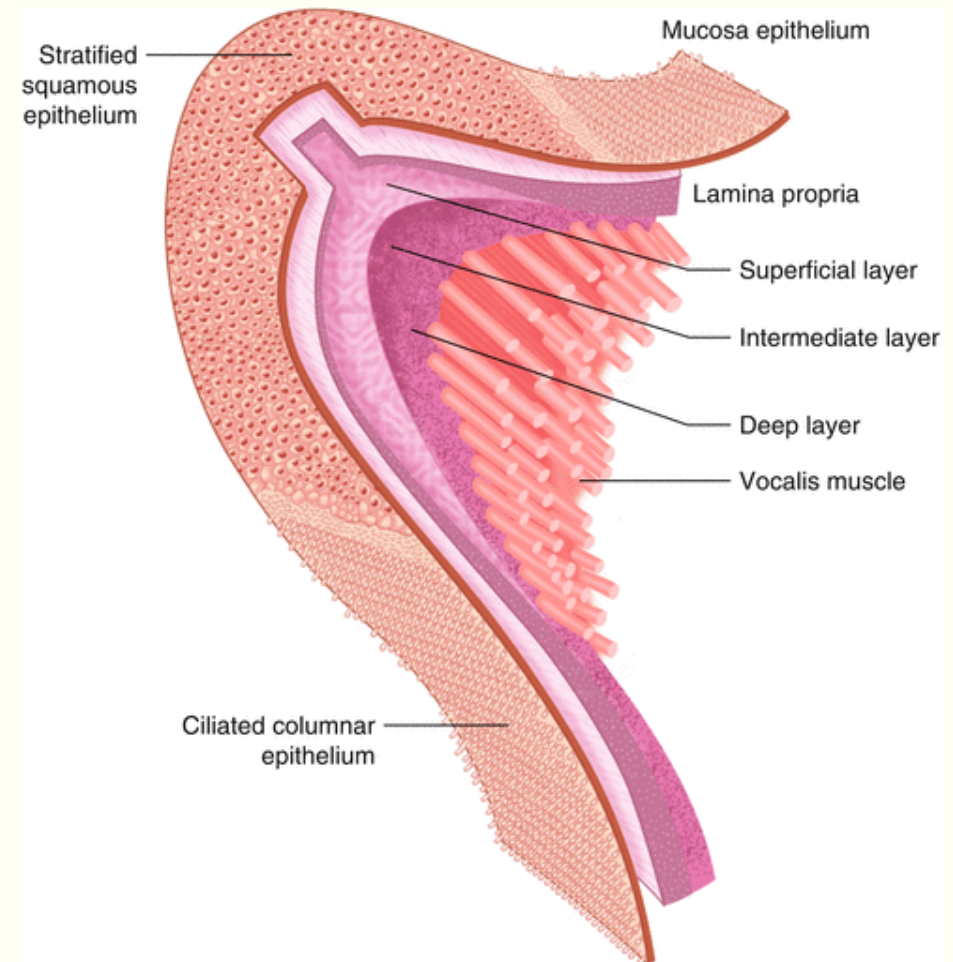
The Larynx

- Composed of three paired cartilages
 - Arytenoid cartilage
 - Ride on high backed upper surface of cricoid cartilage
 - Articulation with cricoid cartilage allows a wide range of movement
 - Posterior attachment of vocal folds
 - Muscular and vocal processes provide point of attachment for thyromuscularis and thyrovocalis muscles
 - Corniculate cartilage
 - Ride on superior surface of each arytenoid
 - Landmark in the aryepiglottic folds
 - Cuneiform cartilage
 - Reside within the aryepiglottic folds
- Hyoid bone
 - Union between the tongue and laryngeal structures
 - Loosely articulates with the superior cornu of the thyroid cartilage



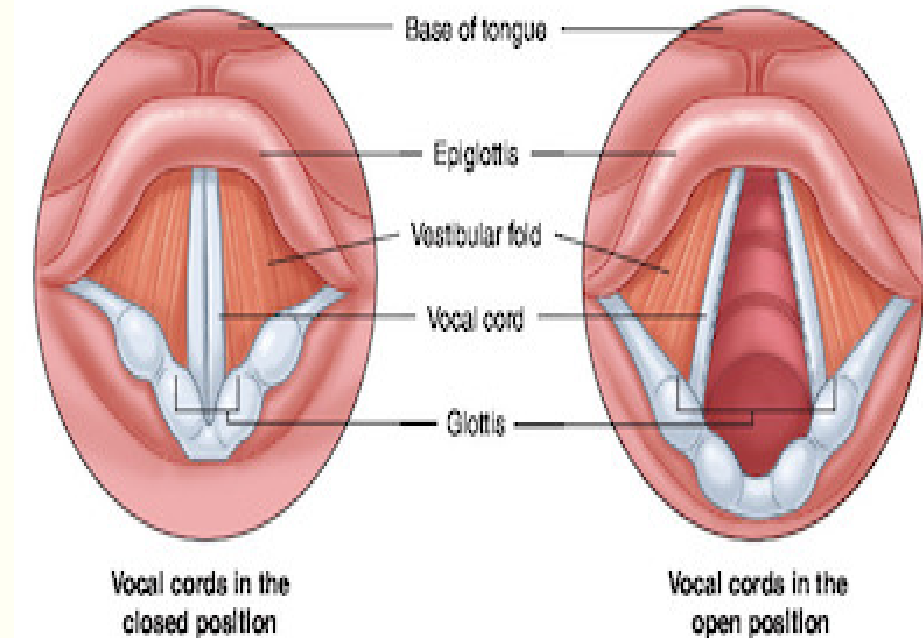
The Vocal Folds

- Five layers of tissue, deepest layer is muscle
- The 5 layers originally proposed by Hirano include:
 - Epithelium
 - Superficial Layer of the Lamina Propria
 - Intermediate Layer of the Lamina Propria
 - Deep Layer of the Lamina Propria
 - Thyrovocalis muscle



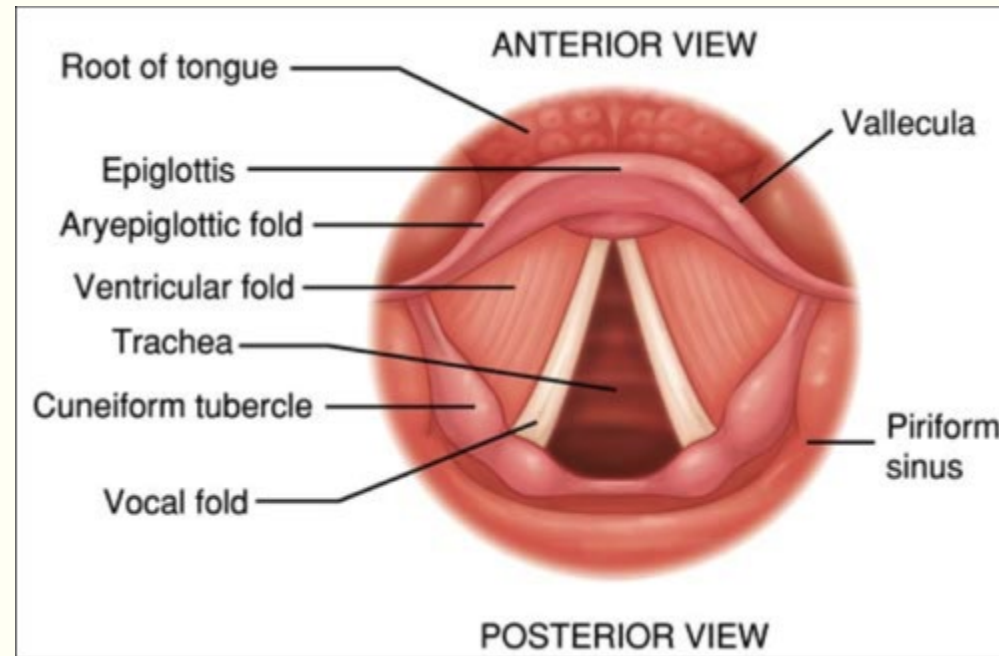
The Vocal Folds

- Glottis
 - Space between the folds
 - Most important laryngeal space for speech
 - Its size and shape changes as a function of the vibratory behavior of the vocal folds
 - When the glottis widens, this is called **abduction**
 - When no air can flow through the glottis this is called **adduction**
- As air passes between the vocal folds, they may be made to vibrate
- Subglottal
 - Area below vocal folds



The Ventricular Folds

- False Vocal Folds



Muscles of the Larynx

The muscles of the larynx are skeletal (i.e. under voluntary control for voice production, controlled by the central nervous system)

Intrinsic

Extrinsic

Muscles of the Larynx: Intrinsic

- The intrinsic laryngeal muscles
 - Found within the larynx
 - Functions:
 1. Adduct
 2. Abduct
 3. Tense
 4. Relax

Muscles of the Larynx: Intrinsic

Thyroarytenoid (TA)

- Referred to as the deepest layer of the vocal fold structure

- 2 sections of the TA:

- Thyrovocalis

- The more medial section
 - Tenses the vocal fold when it contracts

- Thyromuscularis

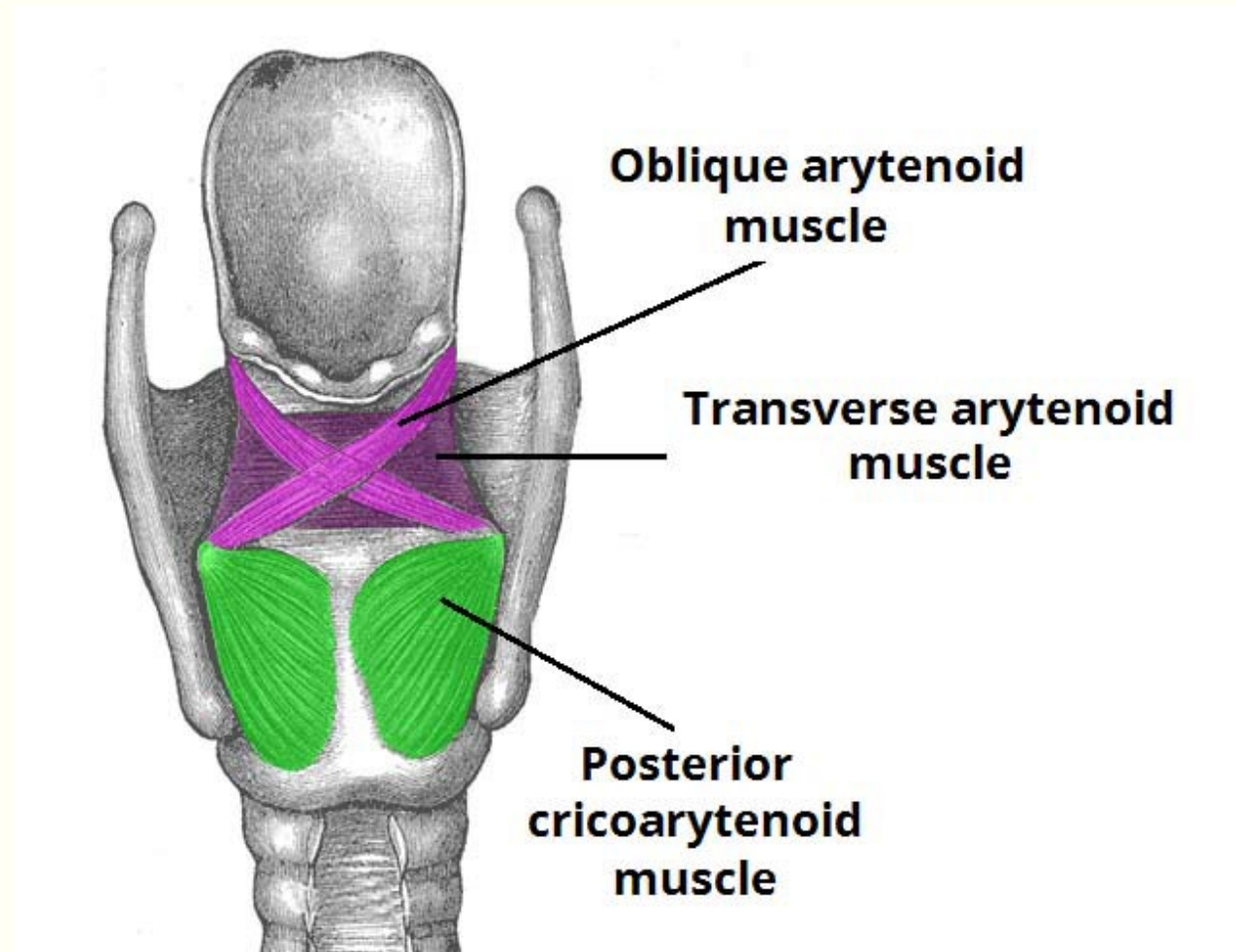
- The more lateral section
 - Relaxes the vocal fold when it contracts

Function: Shortens the vocal folds when it contracts

Muscles of the Larynx: Intrinsic

Posterior cricoarytenoid muscle (PCA)

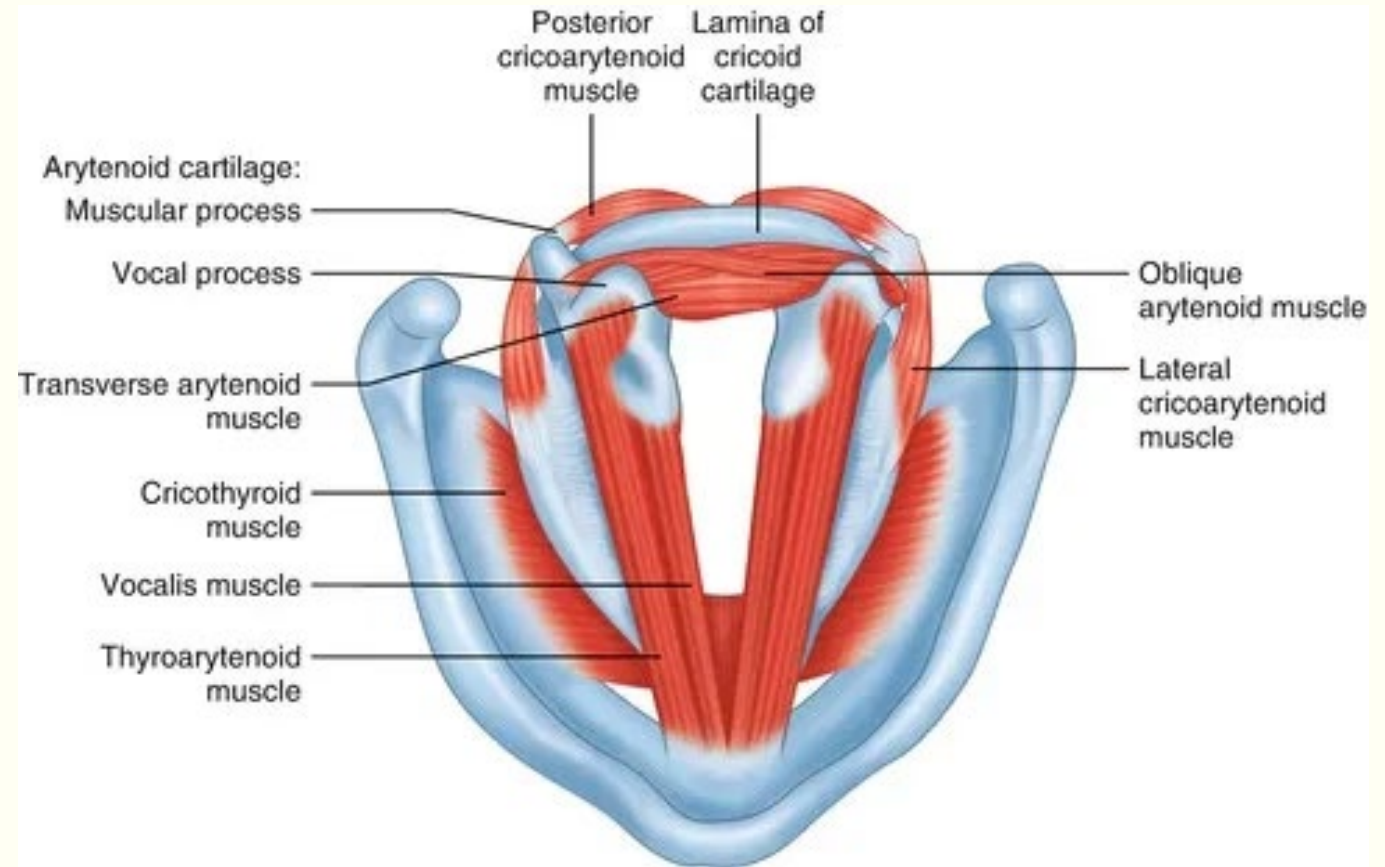
- Function: It abducts the vocal folds by moving the muscular process medially and rotating the vocal process laterally



Muscles of the Larynx: Intrinsic

The lateral cricoarytenoid (LCA)

Function: Upon contraction it adducts the vocal fold by moving the muscular process posterolaterally and the vocal process medially



Muscles of the Larynx: Intrinsic

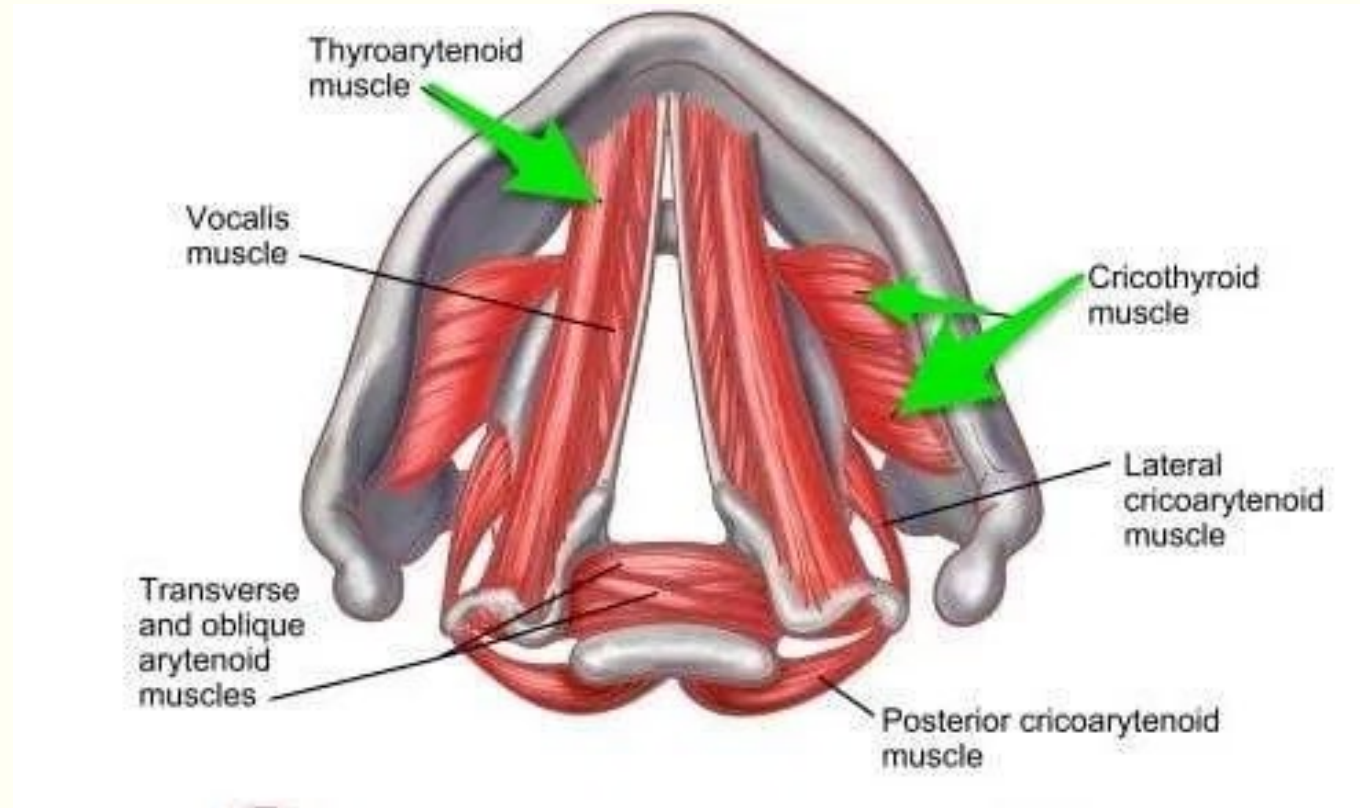
The cricothyroid muscle (CT)

Two sections of the CT belly:

Pars recta

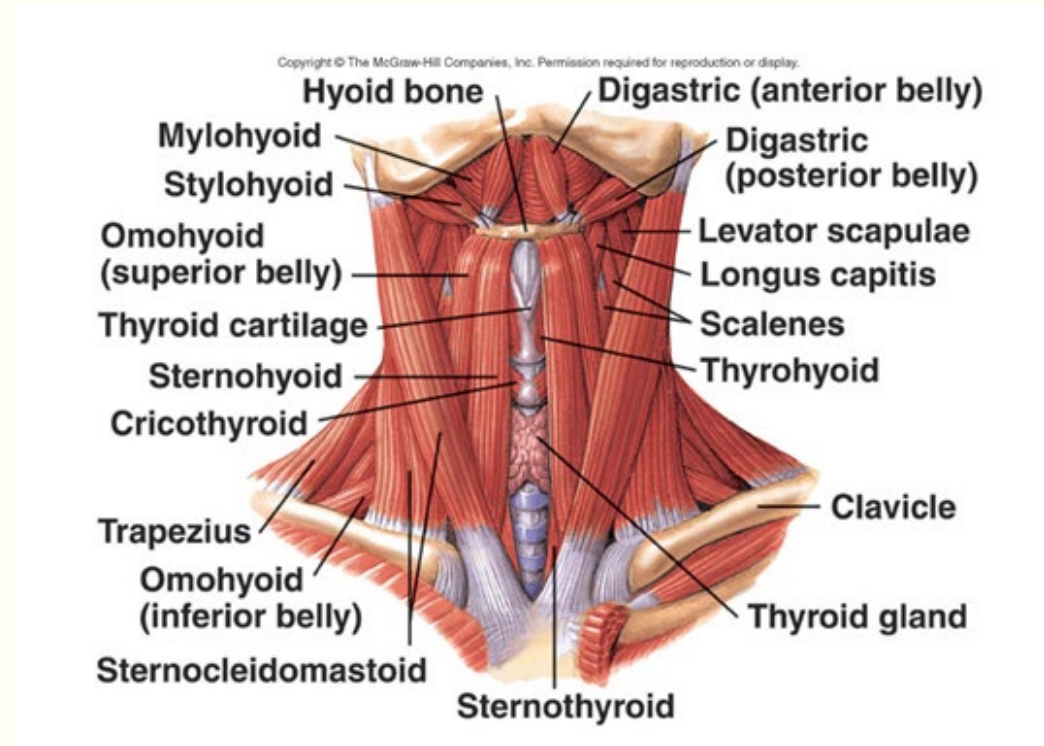
Pars oblique

Function: Tenses the vocal folds



Muscles of the Larynx: Extrinsic

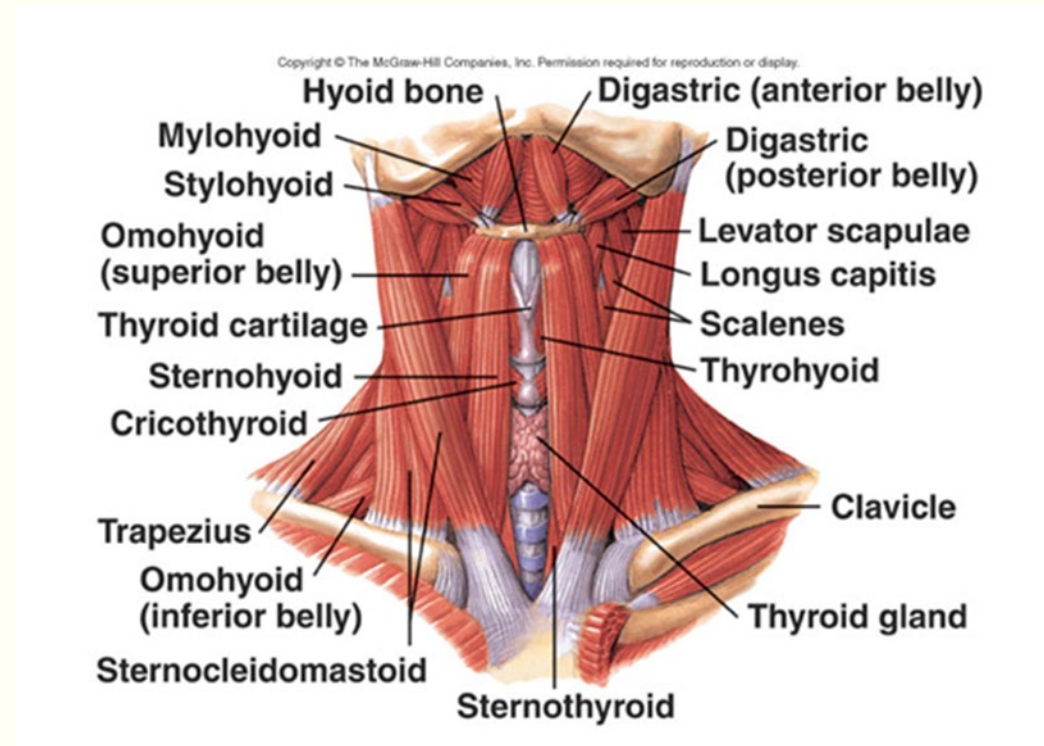
- Functions:
 1. Elevate the larynx within the vocal tract
 - action of the suprahyoid extrinsic muscles
 2. Depress the larynx
 - Action of the infrahyoid extrinsic muscles



Muscles of the Larynx: Extrinsic

Suprahyoid

- Elevate the hyoid bone and larynx primarily with their other functions serving jaw movement:
- These muscles include:
 - Digastric
 - Mylohyoid
 - Stylohyoid
 - Geniohyoid



Muscles of the Larynx: Extrinsic

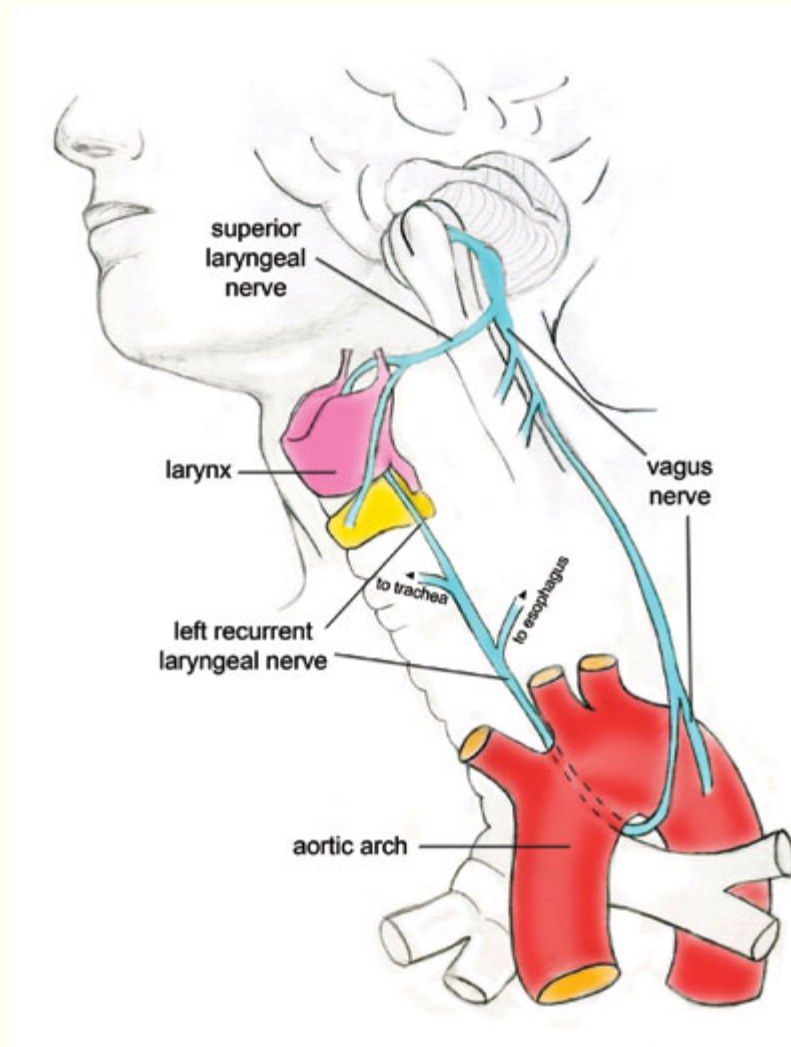
Infrahyoid

- Depress the hyoid and larynx
- These muscles include the:
 - Sternohyoid
 - Sternothyroid
 - Omohyoid
 - Thyrohyoid

Nerve Innervation

Vagus nerve

- Recurrent laryngeal nerve (RLN)
- Superior laryngeal nerve (SLN)



Mechanisms for Changing Pitch

1. Lengthening the vocal folds the relative mass decreases, the cross-sectional area and decreasing thickness of the vocal folds create a faster vibratory rate.
2. Fundamental frequency can be increased by increases in subglottal pressure

Vocal Register



Three registers that relate to the speaking voice:

Pulse register is a fundamental frequency range at the low end of the frequency scale (approximately 35-50 Hz)

Modal register is the range of fundamental frequency most commonly used by a speaker

Falsetto or loft register is a fundamental frequency range at the upper end of the vocal folds vibrating capacity

Mechanisms for Changing Loudness

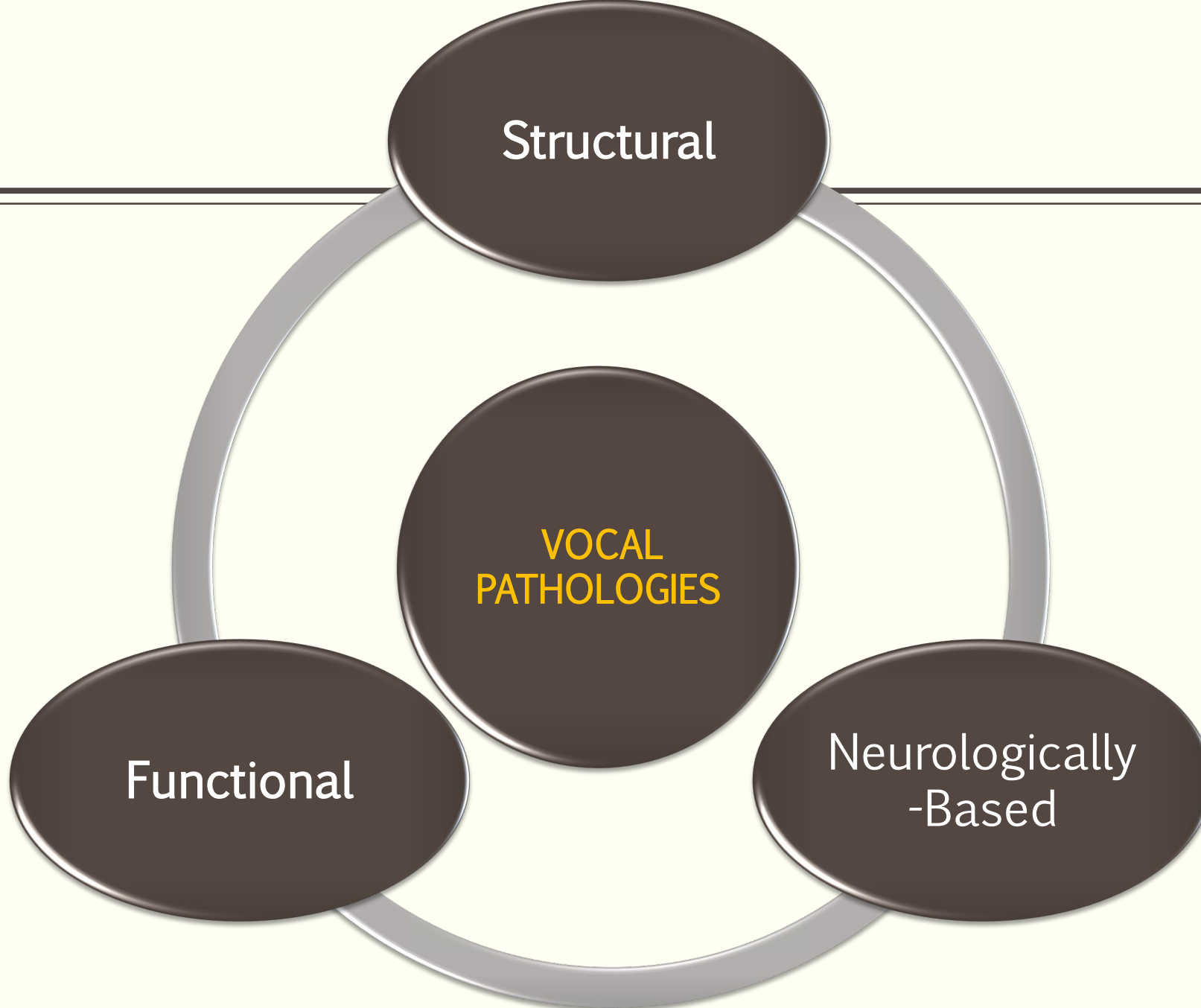
- A doubling of lung pressure can increase the sound source output by 9.5 dB
 - The increased lung pressure causes an increase in peak flow rate and greater vibratory amplitude of the vocal folds

Structural

VOCAL
PATHOLOGIES

Functional

Neurologically
-Based





STRUCTURAL PATHOLOGIES

Vocal Nodules

Description:

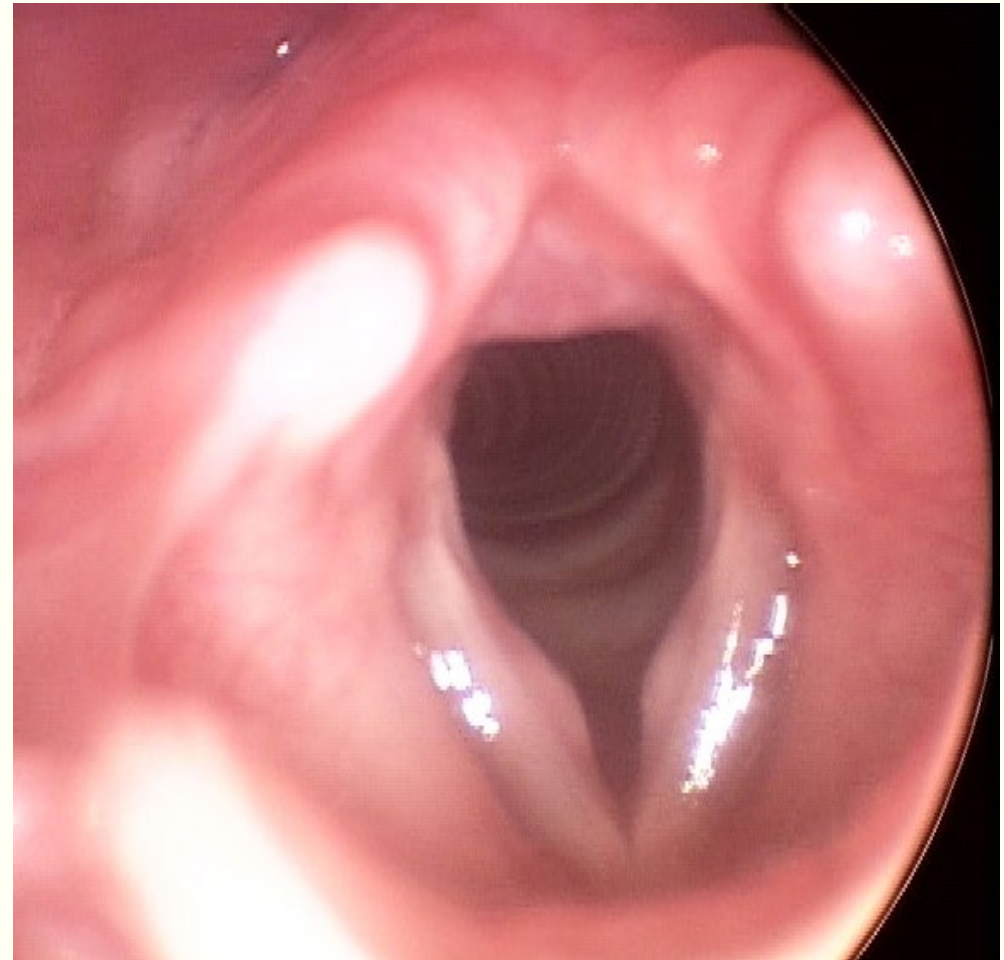
Common benign pathology; Caused from phonotraumatic behaviors; Inflammatory degeneration of the superficial layer of the lamina propria
Typically form bilaterally

Voice Symptoms:

- Voice quality varies from early to mature formation
 - Raspy
 - Hoarse
 - Breathy
 - Easily fatigues
- Singers
 - Loss of vocal range
 - Loss of vocal endurance

Management:

- Behavioral voice therapy
- Vocal hygiene therapy
- Phonosurgery (Not often necessary)



Vocal Fold Polyps

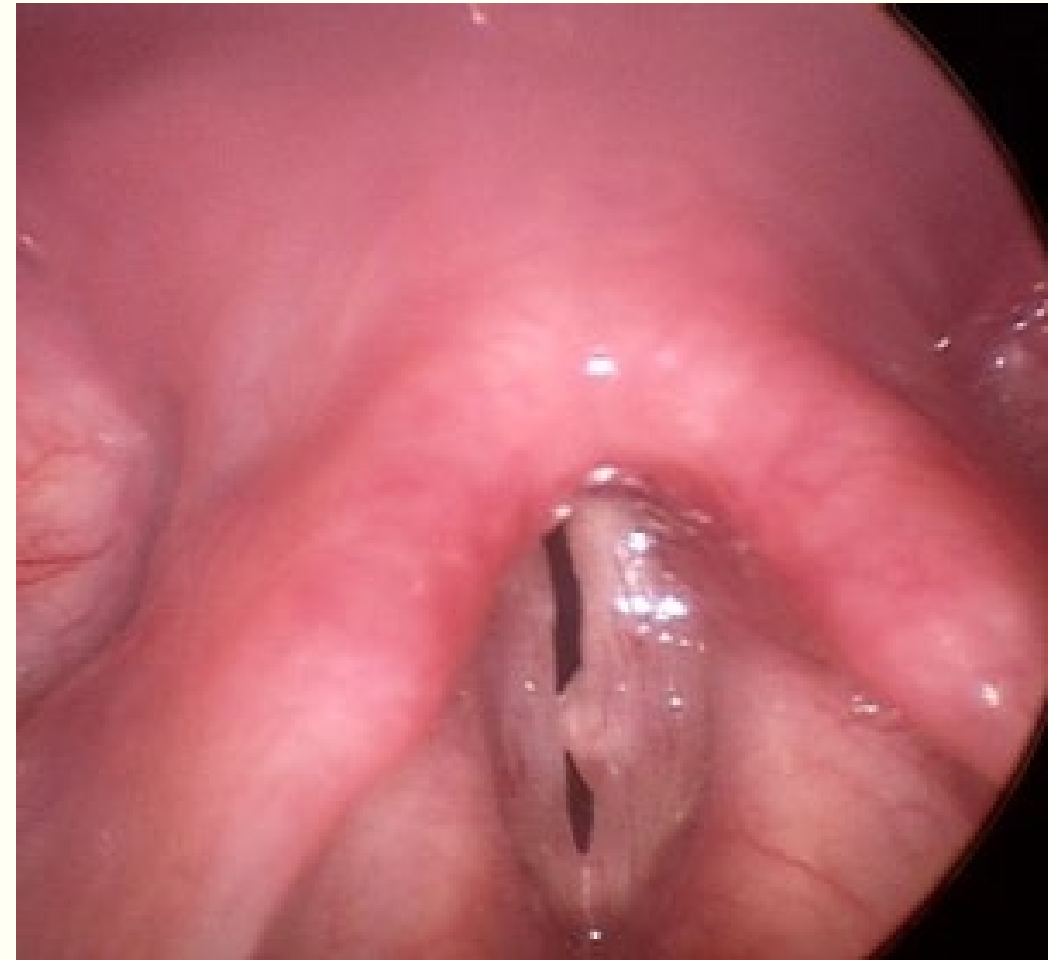Description: Fluid-filled lesion; Develops in the superficial layer of the lamina propria; Has its own blood supply; Typically forms unilaterally

Voice symptoms:

- Typical voice symptoms
 - Hoarseness
 - Roughness
 - Breathiness
 - Globus sensation
 - Effortful phonation
 - Loss of vocal endurance
- A pedunculated polyp that falls below the vocal fold edge may cause difficulty breathing

Management:

- Behavioral voice therapy
- Vocal hygiene
- Medical
- Phonosurgery



Generalized Edema; Reinke's Edema

Description: Buildup of fluid in the superficial layer;
Long-standing trauma or chronic exposure to irritants

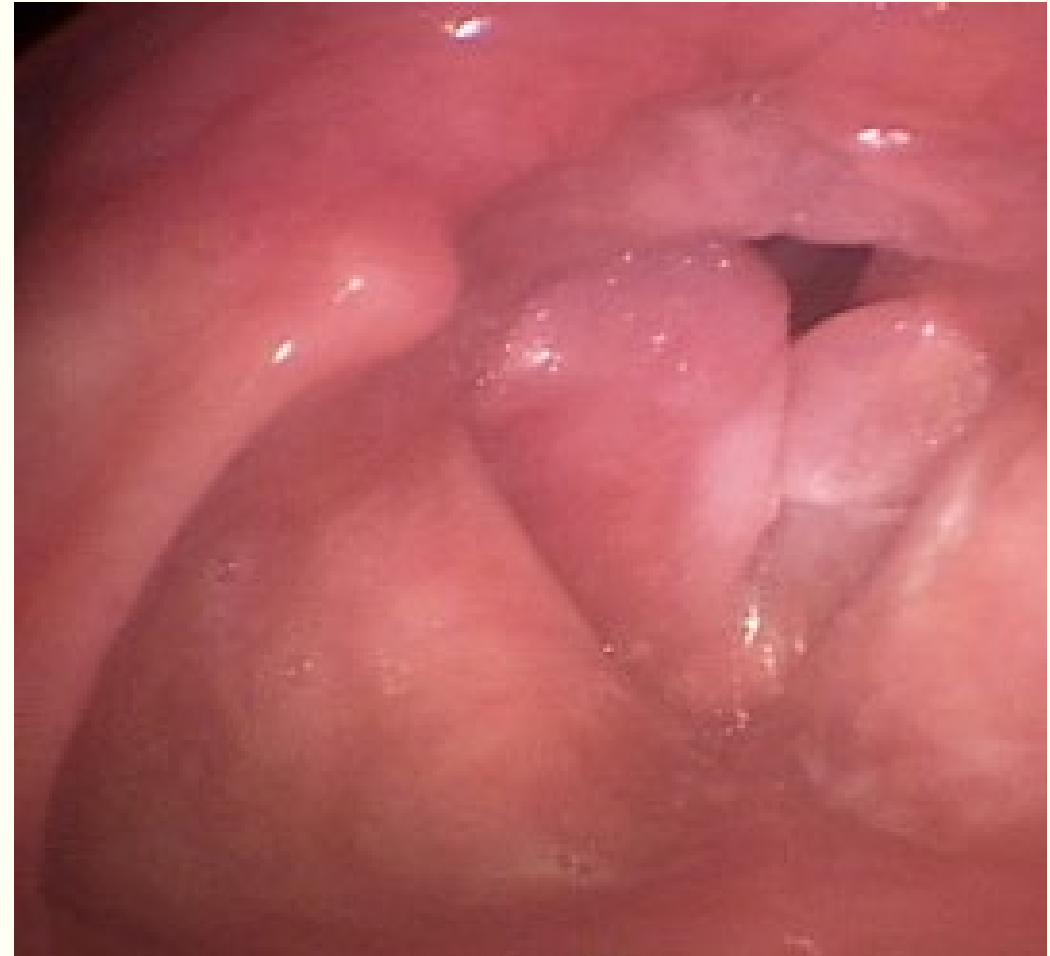- Cigarette smoke
- Laryngopharyngeal reflux

Voice symptoms:

- Voice symptoms
 - Lowered pitch and varying degrees of hoarseness
- Increased vocal fold mass
- Swelling can become large enough to cause symptoms of dyspnea
- Sleep apnea can occur

Management:

- Remove irritant (e.g., smoking)
- Vocal hygiene
- Phonosurgery



Laryngitis

Description:

- Inflammatory condition of the vocal fold mucosa
- Caused by:
 - Reaction to a viral and/or bacterial infection
 - Traumatic conditions
 - Autoimmune diseases

Voice symptoms:

- Generally produces hoarseness
 - Mild
 - Sore throat, cough and a fever
 - Severe
 - Caused by continued voice use during the bout of laryngitis

Management:

- Often resolves with rest and hydration
- Antibiotics
- Necessary to pinpoint the cause of the inflammation
- Remove the causative irritant or pathogen
- Vocal hygiene

Contact Ulcers/Granulomas

Description: Found along the vocal processes

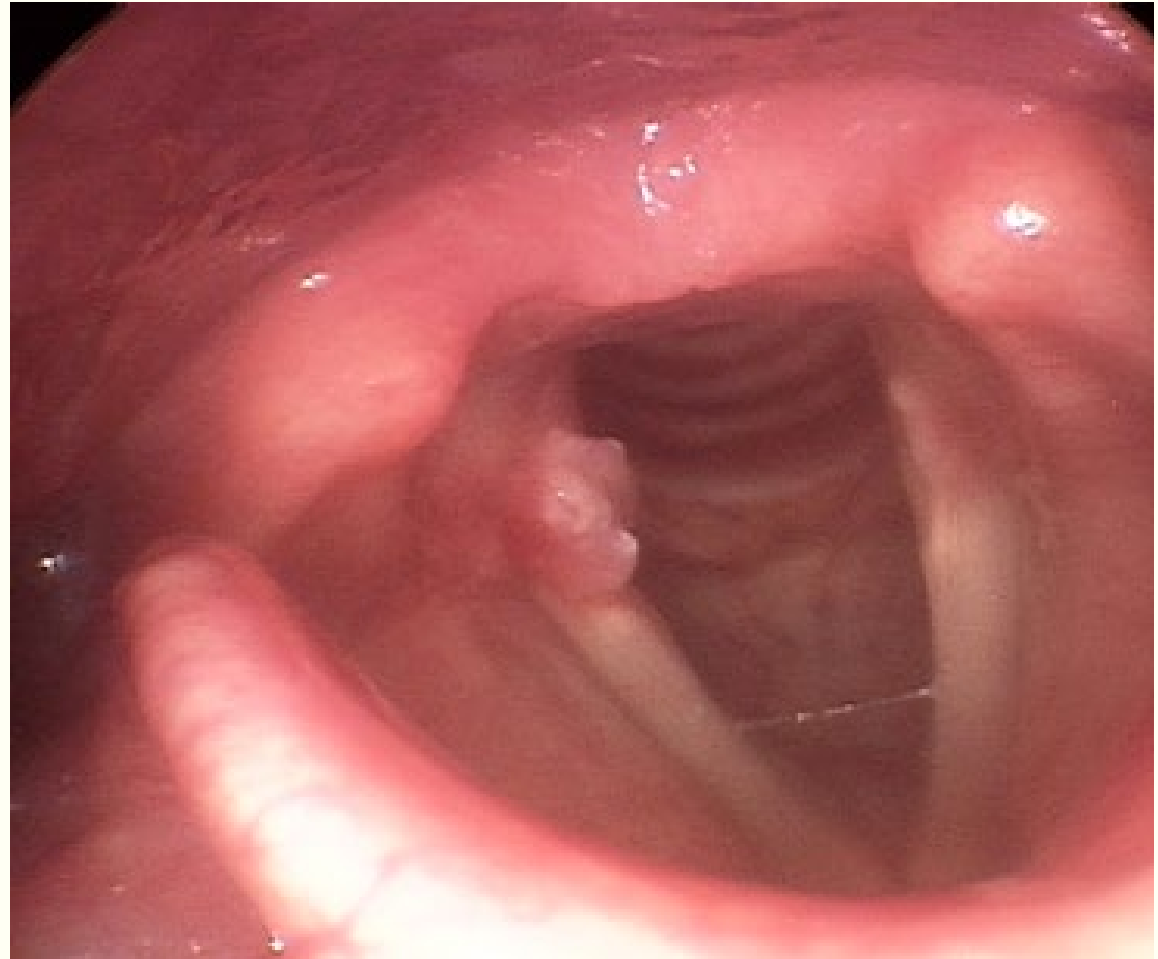
- Contact ulcers- raw sores on the mucus membrane of the arytenoid processes
- Granulomas tend to grow over contact ulcers until cause of irritation is addressed; Unilaterally or Bilaterally; Benign growths that can result from, LPR irritation, Intubation trauma, Phonotrauma

Voice symptoms:

- Hoarseness
- Breathiness
- Difficulty increasing vocal loudness
- Reduced pitch range
- Prolonged warm-up time
- If unilateral may have minimal to no change in voice quality

Management:

- Voice Therapy



Cysts

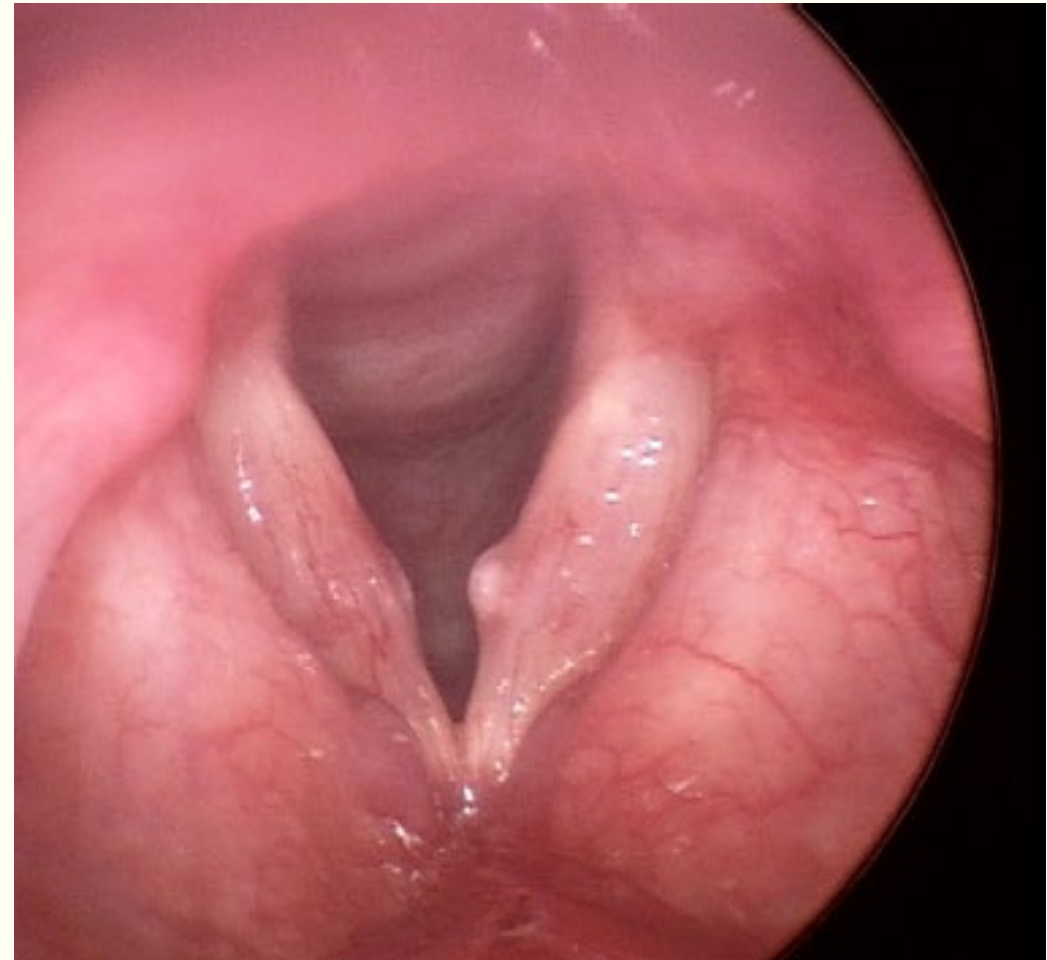
Description: Benign mucus-filled lesion surrounded by a membrane ;Located near the vocal fold surface; The causes (Phonotraumatic behaviors; Glandular blockage); Appear at the mid-membranous portion; Can present congenitally

Voice symptoms:

- Generally result in mild to severe hoarseness
- Voice quality is a function of the size, shape and firmness
- Globus sensation may be present
- Throat clearing and cough

Management:

- Vocal hygiene therapy
- Voice rest
- to help reduce edema surrounding the cyst
- Phonosurgical removal of the cyst is the most common treatment choice
- Microsurgical excision
- Avoid under and over-excision to minimize reoccurrence and inadvertent damage



Candida

Description: Candida is a yeast normally present in the body

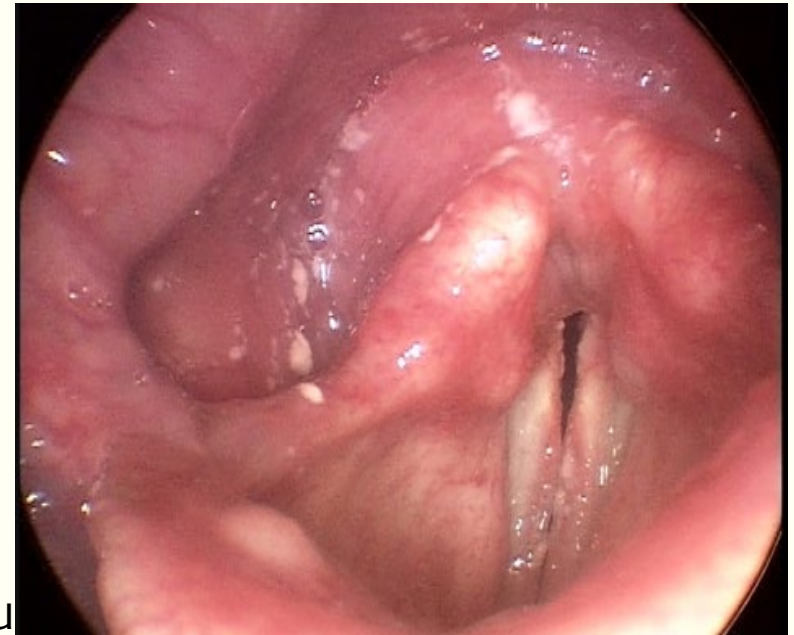- Candidiasis is a fungal infection that occurs as a consequence of weakness within the immune system

Voice symptoms:

- Voice quality
 - Pressed
 - Moderately hoarse
 - Breathy
 - Pain may be present

Management:

- Medication
- Removal of predisposing factors
- Implementation of good vocal hygiene
- Eliminate irritating factors. E.g. - Gastroesophageal reflux
- Increasing hydration
- Voice therapy is often not necessary



Laryngeal Papilloma

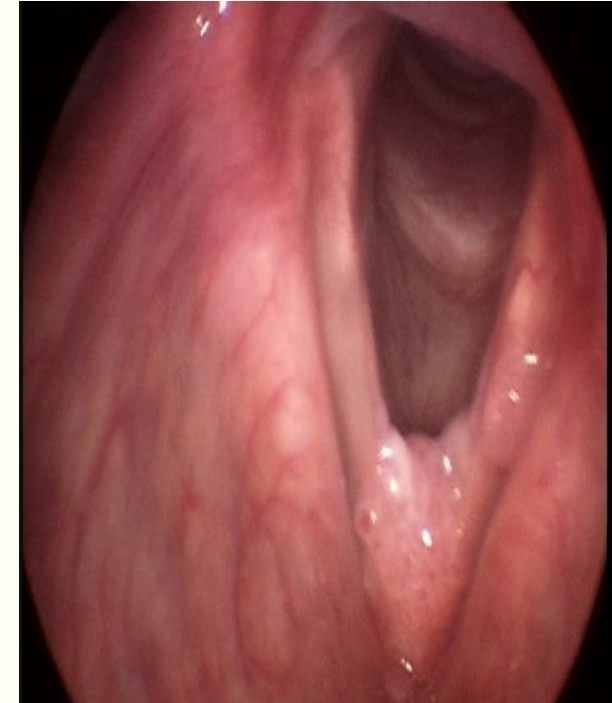
Description: Inflammatory condition of the vocal fold mucosa

Voice symptoms: Generally produces hoarseness

- Mild
 - Sore throat, cough and a fever
- Severe
 - Caused by continued voice use during the bout of laryngitis

Management: Often resolves with rest and hydration

- Antibiotics
- Necessary to pinpoint the cause of the inflammation
- Remove the causative irritant or pathogen
- Vocal hygiene



Cysts

Description: Benign mucus-filled lesion surrounded by a membrane; Located near the vocal fold surface.

Voice symptoms:

- Generally result in mild to severe hoarseness
- Voice quality is a function of the size, shape and firmness
- Globus sensation may be present
- Throat clearing and cough

Management:

- Vocal hygiene therapy
- Voice rest
 - to help reduce edema surrounding the cyst
- Phonosurgical removal of the cyst is the most common treatment choice
 - Microsurgical excision
- Avoid under and over-excision to minimize reoccurrence and inadvertent damage

Laryngeal Web

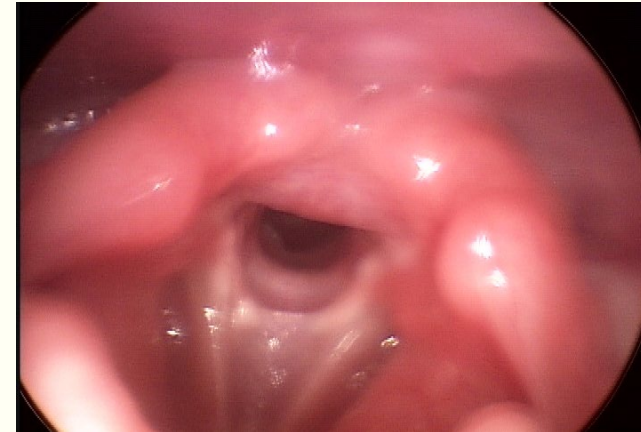
Description: Could be congenital or acquired; Congenital laryngeal webs occur when there is a failure of recanalization during embryonic development; 75% occur at birth; Typically are located anteriorly; Can block up to 75% of the glottal airway

Voice symptoms:

- Voice symptoms
 - Hoarseness
 - Difficulty sustaining phonation

Management:

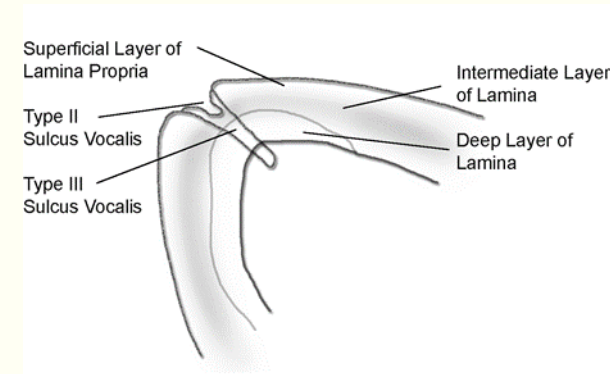
- Resection of the web
 - Either a knife or laser procedure
- A keel may be placed between the vocal fold edges to prevent re-scarring



Sulcus Vocalis

Description: Thinning or loss of the superficial layer of vocal fold tissue
Etiology undefined - linked to smoking

- **Voice symptoms:** Perceived voice quality
- Hoarseness
- Weakness
- Increased effort
- Vocal fatigue



Management:

- Often involve resection of the fibrous tissue and abnormal mucosa from the surface of the vocal fold
- Treatment:
- Autogenous fat and fascia augmentation
- Improvements in vocal quality, glottal closure, mucosal wave excursion, acoustic, perceptual, and phonatory functions
- Other phonosurgical procedures
- Medialization or other injectables
- Materials used are fascia, fat and collagen

Presbylaryngis

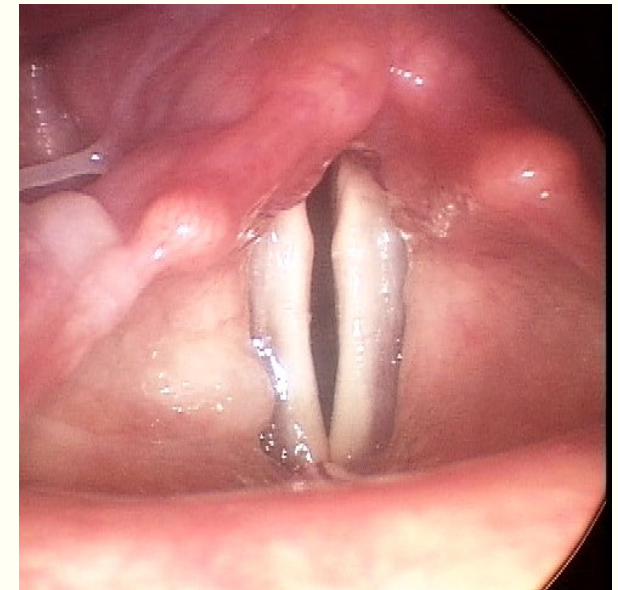
Description: Sarcopenia; Wasting and thinning of muscle tissue
Effects on the thyroarytenoid muscle; Becomes thinner

Voice symptoms:

- Softer, altered pitch with some accompanying roughness
- Tremor may be associated with aging
- Reduced vocal loudness
- Pitch differences are observed between the sexes
 - Male pitch tends to become higher with age
 - Female pitch tends to lower with age

Management:

- Voice therapy
- Emphasis on improving glottal closure
 - Medialization procedures
 - Use of injectables



Leukoplakia/Hyperkeratosis

Description: White plaque like formation occurring on the vocal fold surface

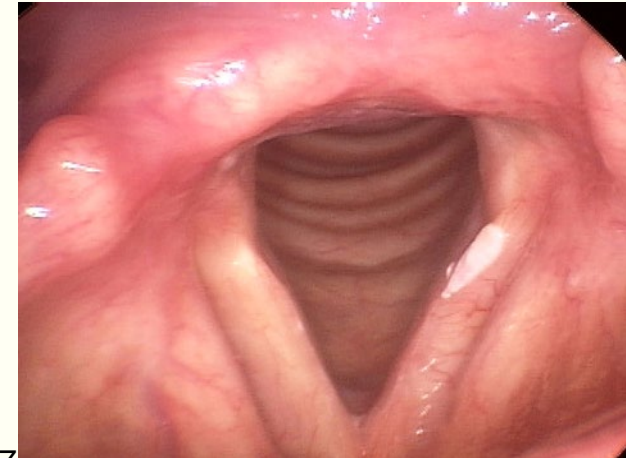
- Usually found at the anterior portion of the vocal fold but may extend into the interarytenoid area
- Considered a precancerous state and should be biopsied

Voice symptoms:Voice quality

- Rough
- Hoarse

Management:

- If biopsy is not found to be atypical then,
 - Vocal hygiene counseling
 - Counseling to indicate that unless the chronic irritation is minimized or removed the cell growth could reach a cancerous state
- Small leukoplakias:
 - Surgical excision usually suffices
- Patients should be followed for at least 3 to 6 months to monitor for recurrence



Dysplasia and Laryngeal Cancer

Description:

Pathologic tissue change in the mucosa; Identified with biopsy

Abnormal cells are not found to be malignant; Often indicative of early cancerous process

Appears whitish or reddish in color due to hypervascularization

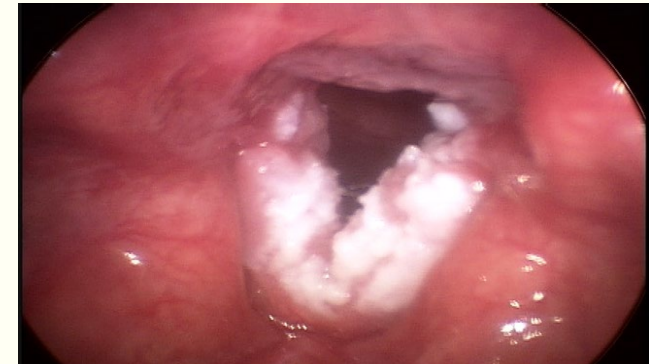Can form a mass, plaque, or irregularity on the vocal fold edge

Voice symptoms:

- Hoarseness
- Change in pitch (typically lower due to the mass effect)
- Vocal strain
- Sore throat or globus sensation
- Persistent cough
- Stridor

Management:

- A combined modality treatment
 - Surgery radiation and chemotherapy
- Prescribed and/or changed based on the stage of diagnosis
- Requires continued cancer surveillance through regular laryngeal examinations



Ankylosis of Cricothyroid Joint

Description: Resulting from injury after a traumatic dislocation; Potentially from intubation; Disease such as inflammation (Rheumatoid arthritis); Results in stiffness and/or fusion of the cricothyroid joint

Voice symptoms:

- Breathy or rough voice quality
- Difficulty prolonging a sustained vowel
- Pain during swallowing

Management:

- Medically by performing vocal fold mobilization under direct laryngoscopy
- Medialization of one or both vocal folds to increase glottic closure for tasks such as speech or cough

Laryngomalacia

Description: Most common cause of inspiratory stridor in infancy; Congenital condition of unknown etiology; Characterized by

- Floppy epiglottis
- Large aryepiglottic folds
- Large arytenoids process

Voice symptoms:

- Intermittent inspiratory stridor
- Starts just after a few days or weeks following birth
- The degree of stridor increases as the depth and rate of breathing is increased

Management:

- Most infants do not require treatment as laryngomalacia resolves with maturation
- When surgery is needed:
 - Aryepiglottic fold incision
 - CO2 laser supraglottoplasty
- Other possible complications to treat:
 - Esophageal reflux disease
 - Upper respiratory infections
 - Heart disease
 - Lung disease
 - Neurologic disease

Vascular Lesions: Varix and Ectasia

Description: Originating in the superficial layer of the lamina propria

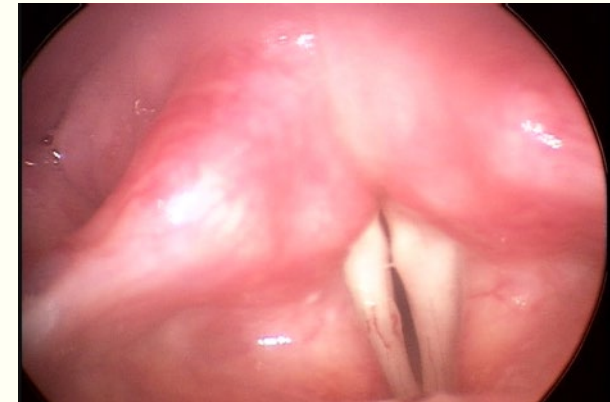- Direct result of phonotrauma
- Midmembranous portion of the vocal fold
- Related to high-pressure phonatory events
 - Shouting and oversinging
- More prevalent in women than men
 - Female hormonal cycle

Voice symptoms:

- Some present with a vocal fold varix or ectasia
- Others present with a dysphonia
 - Loss of vocal range
 - Particularly in the higher frequencies
 - Hoarseness

Management:

- Voice rest until any blood is reabsorbed
- Vocal hygiene
- If surgery is necessary cold instrument dissection is ideal



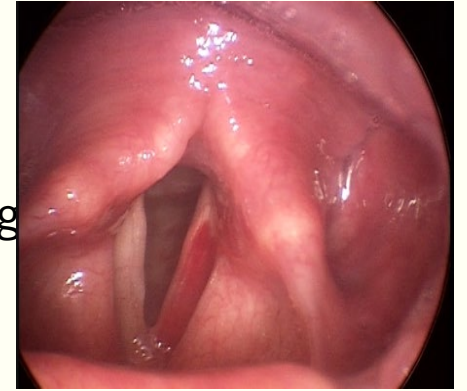
Vascular Lesions: Vocal Fold Hemorrhage

Description: Damage to the tissues as a result of exposure to blood

- Extremely small delicate blood vessels which traverse the various tissue layers

Voice symptoms:

- When superficial layer of the lamina propria is affected the effects can be devastating
 - Dysphonia
 - Complete aphonia
 - Absence of voice



Management:

- Phonosurgical excision of microvascular lesions may prevent a vocal fold hemorrhage
- In the acute phase:
 - Complete and total voice rest in order allow the tissues time to heal
 - Once healed, residual dysphonia can be treated through a variety of augmentative procedures
 - Injection of fat or collagen to the vocal fold to restore vibratory capacities



FUNCTIONAL VOICE DISORDERS

Puberphonia

Description: Adolescent males who have seemingly maladjusted growth of the larynx

- Maintenance of a high-pitched voice
- Psychosocial repercussions for the male who is not past puberty

Voice symptoms:

- The pitch is higher than it should be
- Breathy
- Low vocal loudness

Management:

- Behavioral management
- Voice therapy techniques to reduce the higher pitch
 - Biofeedback computerized software
- Kay Pentax Visipitch
 - Manual laryngeal massage therapy
 - Other relaxation techniques to help reduce muscle tension

Ventricular Phonation

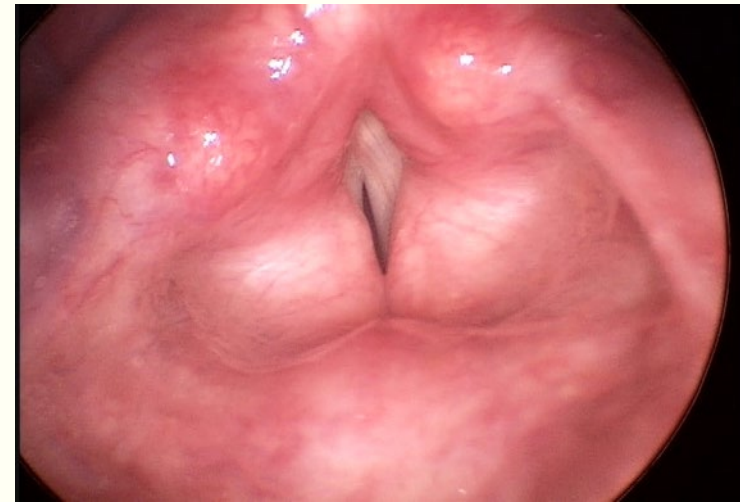
Description: Use of the ventricular folds during voicing instead of, or along with, the true vocal folds
Common conditions with ventricular phonation: Accompanying severe muscle tension; Severe true vocal fold dysfunction; Compensatory technique

Voice symptoms:

- Low pitched
- Reduction in vocal range
- Reduction in loudness
- Pitch variability
- Roughness
- Hoarseness
- Vocal fatigue
- Globus sensation
- Pain in the ears

Management:

- If the true vocal folds are unable to produce voice:
 - Voice therapy
 - Psychotherapy
 - Pharmacological therapy
 - Surgical interventions (excision or laser surgery)



Muscle Tension Dysphonia

Description: Increased muscle activity in the head and neck

- Responses on case history often include:
 - Stress, anxiety, depression, high vocal demand, issues with time management, and general complaints of being overloaded both physically and emotionally
- Other conditions associated with MTD include:
 - Laryngopharyngeal reflux

▪ **Voice symptoms:** Voice quality:

- Strained
- High pitch

When vocal fold tension appears high

- Folds may never adduct
 - Breathiness weakness to the sound quality

Management:

- Voice therapy:
 - Biofeedback
 - Laryngeal relaxation techniques
 - Resonant voice therapy
 - Circumlaryngeal massage
 - Accent method

Transgender/Transsexual Voice Transition

Description: Individuals seeking to change the gender role assigned to them at birth

- Masculinization transition from female to male
- Feminization transition from male to female

- Persons seek voice treatment to assist in producing a voice pitch which is in agreement with their new gender identity

Voice symptoms:

- Pitch of the person transitioning from female to male will be too high
- Pitch of the person transitioning from male to female will be too low
- Other variables to work on:
 - Resonance
 - Intonation
 - Rate
 - Vocal intensity

Management:

- Reducing or increasing the fundamental frequency
 - Biofeedback
 - Use of a hierarchical approach
 - Homework exercises
 - Real-world tasks to help achieve generalization of the therapeutic target
- Modification of loudness
 - Biofeedback techniques
 - Vocal Function Exercises
- Resonance
 - Frontal focus therapy
 - Lessac Madsen Resonant Voice Therapy

Conversion Aphonia

Description: Related to a manifestation of stress, depression, or anxiety; Psychogenic voice disorder; Tends to emerge very quickly; Can be associated with a traumatic event and severe stress; No evidence of a physical or neurologic cause

- Significant functional and social impact

Voice symptoms: No voice on attempted phonation or

- If voicing does emerge it is often high pitched and very strained
- Often pain in the neck area and extrinsic laryngeal muscle tightness when attempting to phonate

Management:

- Psychiatric treatment
- Voice therapy
- Cognitive behavioral therapy
- Antidepressants



NEUROLOGICALLY-BASED PATHOLOGIES

Unilateral True Vocal Fold Paralysis

Description: Complete immobility in one vocal fold; The Recurrent Laryngeal Nerve (RLN); Primarily responsible for vocal fold abduction and adduction; Branch of cranial nerve X, the vagus nerve

Voice symptoms:

- May exhibit
 - Aphonia
 - Completely normal voicing
- Highly variable
- When paralyzed in a highly abducted position:
 - Breathy
 - Weak
- Dysphagia is common
 - Due to difficulty closing the glottis

Management:

- Direct trauma
 - “Wait and see” approach is often preferred
 - 6 month time window
- Behavioral voice therapy to facilitate vocal fold closure
 - Pushing Techniques
 - Vocal Function Exercises
 - Resonant Voice Therapy
 - Lee Silverman Voice Therapy (LSVT)
- Surgical interventions consist of
 - Medialization (Ishiki Type I thyroplasty)
 - Vocal fold augmentation
 - Reinnervation surgical procedures

Bilateral True Vocal Fold Paralysis

Description: Commonly results from

- Surgical trauma, malignancies, endotracheal intubation neurologic disease, or idiopathic causes
- Life threatening when the folds are fixed in the paramedian position
- Can sometimes be confused with bilateral arytenoid cartilage fixation

Voice symptoms:

- Voice is highly variable:
 - Completely normal phonation
 - Complete aphonia
 - Inspiratory stridor
 - May signal airway obstruction

Management:

- If no emergent need
 - “Wait and see” approach
- Concern for airway patency:
 - Tracheotomy
 - Cordectomy
 - Widen the glottis
 - Pacing strategies implantable electrical stimulators
 - Secondary adductor muscle block
 - Botulinum toxin

Superior Laryngeal Paralysis

Description: The superior laryngeal nerve (SLN)

- Branch of the vagus nerve
- Bilaterally innervates the cricothyroid
- Occurs through:
 - Trauma
 - Neoplastic
 - Infectious conditions with viral infections
- Damaged during surgery of the thyroid gland

Voice symptoms:

Weak, breathy voice, hoarse and disruption in vocal frequency ranges

Management:

“Wait and see” approach

Surgical interventions:

- Fusion of the thyroid and cricoid cartilages
- Other procedures are being tested in the animal model

Spasmodic Dysphonia

Description: Unknown origin although thought to be related to basal ganglia dysfunction

- Affects the laryngeal adductory and abductory muscles during phonation
- Two Types:
 - Adductor SD
 - Irregular closure of the vocal folds
 - Abductor SD
 - Mixed SD

Voice symptoms: The voice quality:

- Abductory
 - Weak and breathy
- Adductory
 - Strained
- Abductory and adductory spasms
 - Perceived as stoppages in voice
 - Sustained vowel production
 - Delayed onset
- ADSD is often confused with muscle tension dysphonia (MTD)

Management:

- ADSD
- Behavioral therapies may play a role in the management of ADSD

Essential Voice Tremors

Description: Hyperkinetic movement disorder

Voice symptoms:

- Easy to identify perceptually during vowel prolongation
- Audible and rhythmic cycles of the tremor occurring every 4 to 6 Hz
- Also characterized by
 - Pitch and voice breaks
- Difficulty differentiating essential voice tremor from adductor spasmodic dysphonia
- Laryngeal EMG can help differentiate between the two

Management:

- Pharmacologic management:
 - Beta-blockers and propranolol and metoprolol
- Other drug treatments include:
 - Use of anticonvulsants, benzodiazepines, calcium channel blockers, and Botox
- Deep brain stimulation

Myasthenia Gravis

Description: Due to reductions in the peripheral nervous system; Results in a severe decline in muscle's ability to contract; Muscle weakness

Voice symptoms:

Inspiratory stridor, reduced vocal loudness, monotone voice, hypernasality, hoarseness, and tremor

Management:

Pharmacologic treatments

- Anticholinesterase agents
- Immunosuppressive

A surgical option - Thymectomy

Hypophonia Associated With Parkinson's Disease

Description: Neurodegenerative disease of the extrapyramidal system

Voice symptoms:

- Decreased vocal pitch and loudness range
- Breathiness
- Roughness
- Hoarseness
- Vocal tremor

Management:

- Difficult to treat
- Heterogeneous symptoms
- Vary with time of day, medication state, mood, age, sex, disease severity, patient motivation
- Insufficient evidence to support speech therapy as a sole treatment in any indication of PD
- Expiratory muscle strength training (EMST)

Multiple Sclerosis

Description:

Autoimmune and inflammatory disease of neurogenic origin; Demyelination and axonal damage

- Progressive disability

Voice symptoms:

- Abnormally long pauses between words or syllables
- Words are slurred
- Hypernasal sound quality
- Difficulty raising the vocal loudness
- Weak phonation
- Disturbances of the respiratory cycle

Management:

- No management therapies modify the course of MS
- Symptomatic treatments
- Pharmacologic therapies
 - Immune modulating drugs
 - Interferon beta 1a and 1b, chemotherapeutic
 - Corticosteroids such as prednisone and pain medications
 - Antidepressants
- Diet and lifestyle
 - Modifications
 - Exercise therapies



ASSESSMENT

Assessment

Case History

Self-Assessment

Oral-Peripheral Examination

Assessment of Respiration

Auditory-Perceptual Assessment

Subjective Assessment Based on Clinical Impressions of the SLP

Instrumental Assessment: Laryngeal Imaging

Acoustic Assessment

Aerodynamic Assessment



TREATMENT

Treatment

- Direct
- Indirect
 - Patient
 - Counseling

Treatment Options

- **Vocal Hygienic:** eliminate any behaviors that cause trauma to the structural health and function of the vocal folds

Treatment Options

Physiologic Voice Therapy: Direct exercises are used to activate the laryngeal muscle and work other subsystems, such as respiratory and supraglottal systems

- Accent Method
- Conversation Training Therapy (CTT)
- Cup Bubble/Lax Vox
- Expiratory Muscle Strength Training (EMST)
- Lee Silverman Voice Treatment (LSVT®)
- Manual Circumlaryngeal Techniques
- Phonation Resistance Training Exercise (PhoRTE)
- Resonant Voice Therapy
- Stretch and Flow Phonation
- Vocal Function Exercises (VFEs)

Treatment Options

- **Eclectic Therapy:** Uses multiple behavioral therapy orientations to address patients' care

Treatment Options

Symptomatic Voice Therapy: Direct exercises are used to activate the laryngeal muscle and work other subsystems, such as respiratory and supraglottal systems

- Amplification
- Auditory Masking
- Biofeedback
- Chant Speech
- Confidential Voice
- Glottal Fry
- Inhalation Phonation
- Semi-Occluded Vocal Tract (SOVT) Exercises

References

Boone, D.R., McFarlane, S.C., Von Berg, S.L., & Zraick, R.I. (2020). *The voice and voice therapy* (10th ed.). Boston, MA: Pearson.

Sapienza, C., & Ruddy, B.H. (2012). *Visual examination of voice disorders* (2nd ed.). San Diego, CA: Plural Publishing.

Stemple, J.C., Roy, N., & Klaben, B.K. (2014). *Clinical voice pathology: Theory & management* (5th ed.). San Diego, CA: Plural Publishing.