Adult Dysphagia Praxis Review

SPONSORED BY :
NATIONAL BLACK ASSOCIATION OF SPEECH LANGUAGE & HEARING

PRESENTER
LATASHA W. BAILEY M.S.; CCC-SLP

Financial Disclosure Statement

I am receiving a speaking fee from the National Black Association of Speech Language and Hearing for this presentation.

I have no relevant non-financial relationships to disclose.

Who Am I?

LATASHA WEATHERSPOON BAILEY
M.S.; CCC-SLP

- Southern University and A&M College Graduate (B.S. & M.S.)
- Clinical Manager at Therapy 2000
- Texas Speech and Hearing Association Medical Committee Member
- 9 Years Medical SLP Experience
- Feeding and Swallowing Specialist

OBJECTIVES:

- The learner will identify elements of a normal swallow in the adult population.
- The learner will describe characteristics of dysphagia in the adult population.
- The learner will identify and discuss the anatomy of the swallow.
- The learner will recall the stages of the swallowing process and identify deficits at the various phases.
- The learner will identify and recall the role of the SLP in team approach dysphagia diagnosis and treatment.
- The learner will recall elements of evaluation of swallowing disorders.
- The learner will describe the methods of dysphagia intervention.
- The learner will identify a variety of diagnoses, surgical procedures, and medications that cause dysphagia.
- The learner will utilize critical thinking and analysis to respond to case study questions related to dysphagia.

Dysphagia Defined

Dysphagia is defined as problems involving the oral cavity, pharynx, esophagus, or gastroesophageal junction (ASHA 2007).

Dysphagia is difficulty swallowing caused by disruption at any phase of the swallow.

Dysphagia

Malnutrition and dehydration, aspiration pneumonia, compromised general health, chronic lung disease, choking, and even death may be a consequence of dysphagia.

Adults with dysphagia may also experience disinterest and/or less enjoyment of eating or drinking and/or embarrassment or isolation in social situations involving eating.

Dysphagia may increase caregiver burden and may require significant lifestyle alterations for the patient and the patient's family.

ANATOMY & PHYSIOLOGY OF THE SWALLOW

Muscles of Face

A comparison chart is a helpful tool in decision making. In one glance, the features and qualities of a product, service, place, concept or idea can be juxtaposed with many different items. It can contain quantitative or qualitative information, and is useful in marketing and research, among others.

MUSCLE NAME	ACTION	ORGIN	INSERTION	CRANIAL NERVE
Orbicularis Oris	Closes, opens protrudes and twists lips.	Neighboring muscles mostly buccinators. Many layers around lips.	Skin around lips and angles of the mouth.	Facial CN VII
Zygomaticus Major	Draws lip upward, draws angle of mouth upward; smiling muscle.	Zygomatic Bone	Fibers of the orbicularis oris; angle of the mouth.	Facial CN VII
Zygomaticus Minor	Draws upper lip upward and outward.	Zygomatic Bone	Orbicularis oris in upper lip.	Facial CN VII
Levator Labii Superior	Pulls up or elevates upper lip	Below infraorbital foramen in maxilla	Orbicularis oris in upper lip.	Facial CN VII
Mentalis	Pulls up upper lip	Pulls up upper lip	Pulls up upper lip	Facial CN VII
Levator anguli oris	Pulls down corners of mouth	Canine fossa of maxilla	lower lip near angle of the mouth	Facial CN VII

Muscles of Face

A comparison chart is a helpful tool in decision making. In one glance, the features and qualities of a product, service, place, concept or idea can be juxtaposed with many different items. It can contain quantitative or qualitative information, and is useful in marketing and research, among others.

MUSCLE NAME	ACTION	ORGIN	INSERTION	CRANIAL NERVE
Buccinator	Flattens cheek; holds food in contact w/ teeth; retracts angles of the mouth	Alveolar Process of maxilla, buccinators ridge of mandible	Angle of mouth orbicularis oris	Facial CN VII
Mentalis	Pushes up lower lip; raises chin.	Incisor fossa of mandible	Skin at chin level	Facial CN VII
Risorius	Draws corners or angle of mouth outward; Causes dimples; strain expression to face	Platysma, fascia over the masseter skin	Angle of mouth orbicularis oris	Facial CN VII

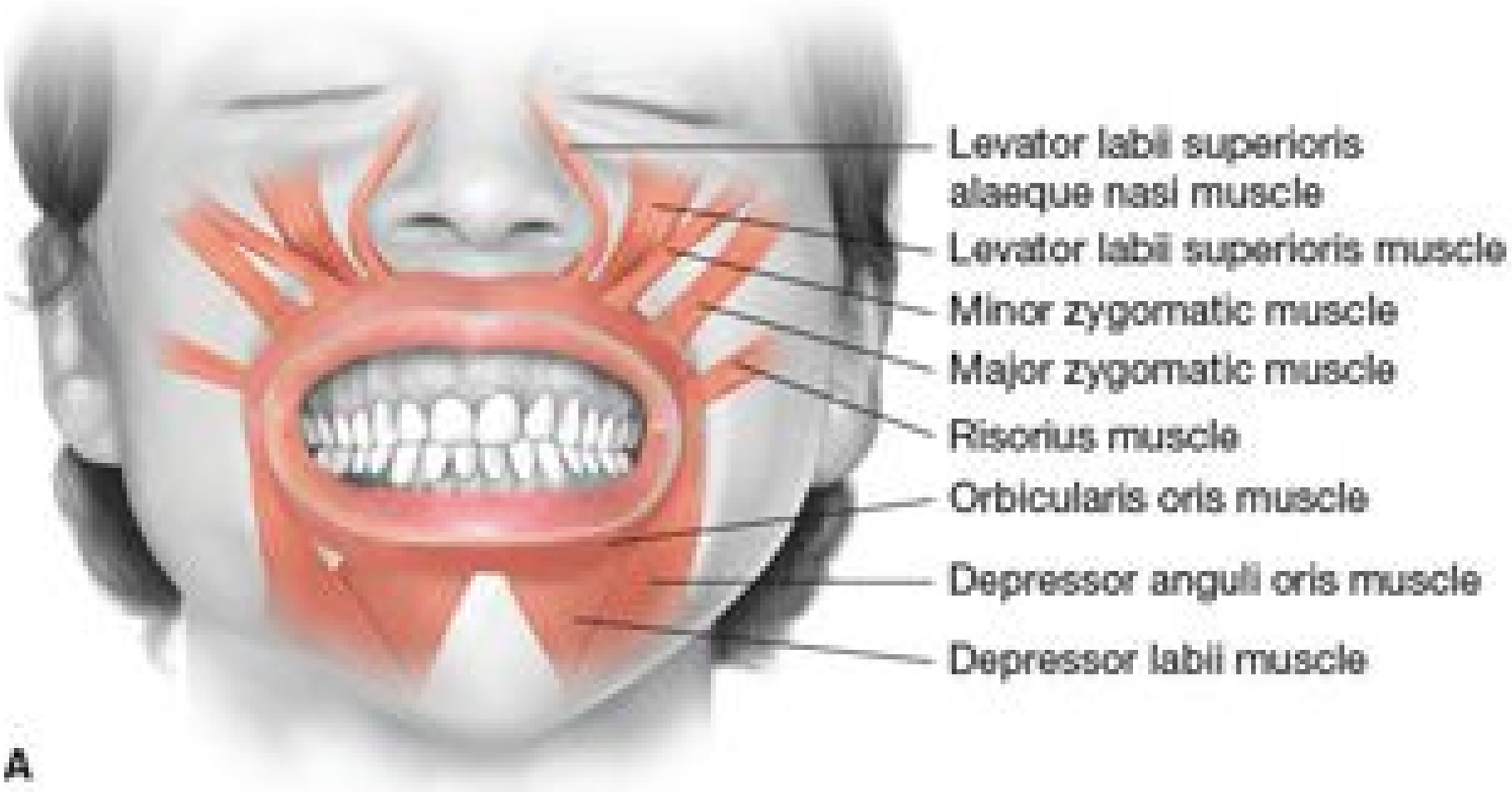
Levator labii superioris alaeque nasi muscle
Levator labii superioris muscle
Minor zygomatic muscle
Major zygomatic muscle
Risorius muscle
Orbicularis oris muscle
Depressor anguli oris muscle
Depressor labii muscle
A

Muscles of Mastication

A comparison chart is a helpful tool in decision making. In one glance, the features and qualities of a product, service, place, concept or idea can be juxtaposed with many different items. It can contain quantitative or qualitative information, and is useful in marketing and research, among others.

MUSCLE NAME	ACTION	ORGIN	INSERTION	CRANIAL NERVE
Temporalis	Elevates/Closes mandible; crushes food between molars	Temporal fossa of skull	Ramus and coronoid process of mandible	Trigeminal CN V
Masseter	Elevates/Closes mandible; lateral movement of mandible for chewing.	Zygomatic arch	Ramus of mandible	Trigeminal CN V
Lateral Pterygoid	Depresses, opens, protrudes mandible; side to side movement of mandible	Great WIng of sphenoid and lateral pterygoid plate	Neck of condyle of mandible	Trigeminal CN V
Medial Pterygoid	Elevates or closes mandible	Palatine bone, lateral pterygoid plate, tuberosity of maxilla	Ramus of mandible	Trigeminal CN V

Quiz Question

Which of the following communication disorders is commonly associated with dysphagia?

a. Aphasia

b. Ataxic Dysarthria

c. Flaccid Dysarthria

d. Organic Voice Tremor

Flaccid dysarthria and dysphagia are both disorders likely to be characterized by flaccidity or weakness of the oromotor and laryngeal mechanism resulting from cranial nerve damage. These two disorders frequently co-exist.

We know that its not aphasia because that is a language impairment. Ataxic dysarthria occurs from cerebellar damage and dysphagia typically does not often co-occur with this type of damage. Organic voice tremor is a laryngeal dysfunction that does not affect oromotor function.

Muscles of Palate

A comparison chart is a helpful tool in decision making. In one glance, the features and qualities of a product, service, place, concept or idea can be juxtaposed with many different items. It can contain quantitative or qualitative information, and is useful in marketing and research, among others.

MUSCLE NAME	ACTION	ORGIN	INSERTION	CRANIAL NERVE
Levator veli palatini	Raises soft palate	Apex of temporal bone	Palatine aponeurosis of soft palate	Vagus and Accessory
Tensor Veli Palatini	Stretches Soft palate	Fossa of Sphenoid bone	Palatine aponeurosis of soft palate	Trigeminal
Palatoglossus	Raises back of tongue	Under surface of soft palate	Side of Tongue	Vagus and Accessory
Palatopharyngeous	Pulls up upper lip	Soft palate.	Pharengeal wall	Vagus and Accessory
Uvulae	Shortens and raises uvula	Posterior nasal spine.	Into uvula to form its content	Vagus and Accessory

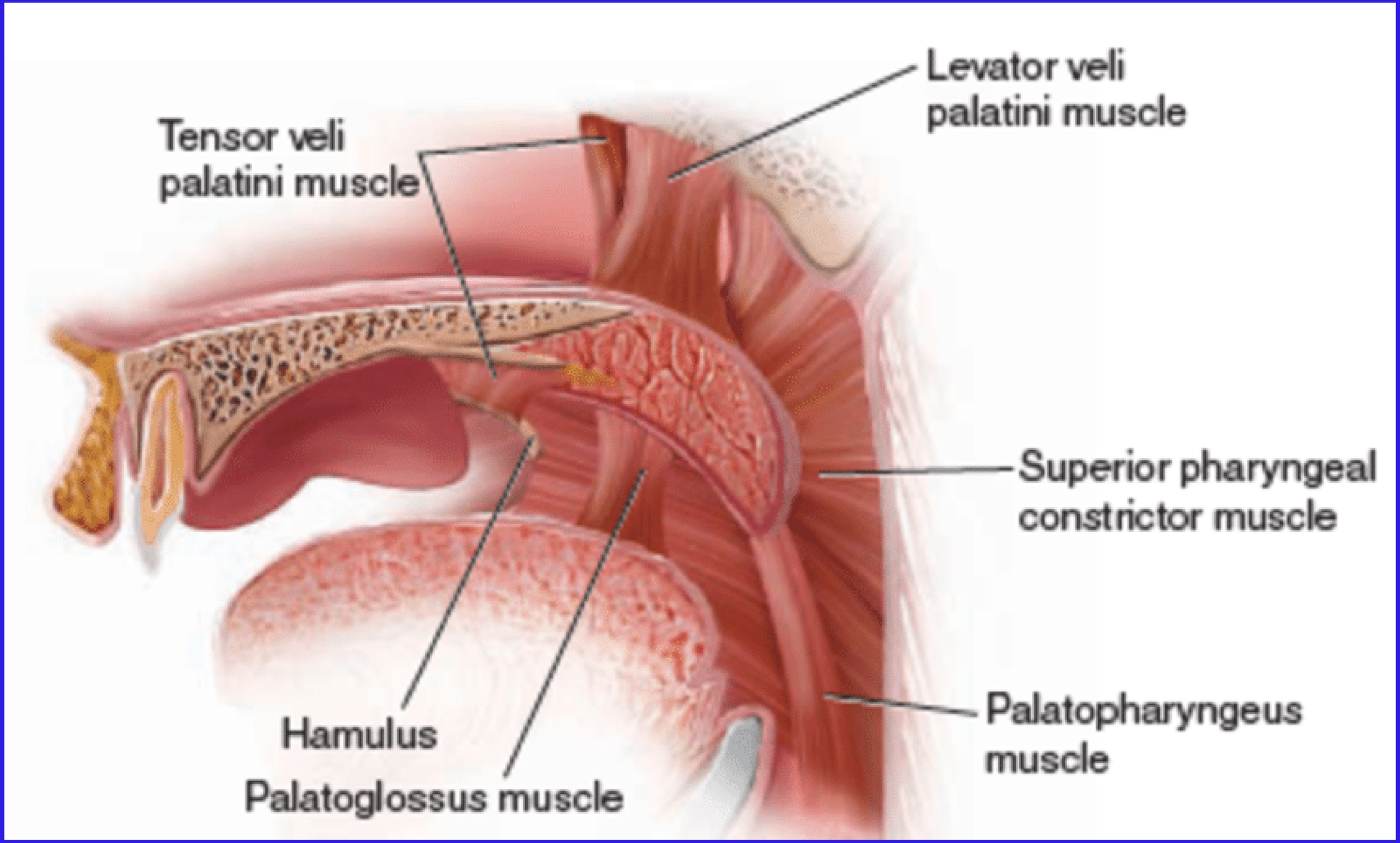
Levator veli
palatini muscle
Tensor veli
palatini muscle
Superior pharyngeal
constrictor muscle
Hamulus
Palatoglossus muscle
Palatopharyngeus
muscle

Suprahyoid Muscles

MUSCLE NAME	ACTION	ORGIN	INSERTION	CRANIAL NERVE
Mylohyoid (anterior belly digastric)	Elevates tongue and floor of mouth; depresses jaw when the hyoid is in fixed position	Inner surface of mandible	Upper border of hyoid bone	Trigeminal
Digastric	Pulls hyoid bone forward and depresses mandible	Intermediate tendon by loop of fascia to hyoid bone	Lower border of mandible	Trigeminal
Geniohyoid	Depresses mandible.	Mental spine of mandible	Hyoid bone	Cervical (C1&C2) through hypoglossal
Stylohyoid	Elevates hyoid and tongue base	Stylohyoid process of temporal bone	Body of hyoid .	Facial CN VII

Suprahyoid Muscles

MUSCLE NAME	ACTION	ORGIN	INSERTION	CRANIAL NERVE
Hyoglossus	Depresses tongue	Greater cornu of hyoid	Into sides of tongue	Hypoglossal
Genioglossus	Protrusion and depression of tongue	Upper genial tubercle of mandible	Hyoid inferior tongue, and tip of tongue.	Hypoglossal
Styloglossus	Elevates up and back	Anterior border of styloid process	Into side of tongue	Hypoglossal
Palatoglossus	Narrow fauces and elevates posterior tongue	Anterior surface of soft palate	Dorsum and side of tonge	Glossopharyngeal, vague and accessory

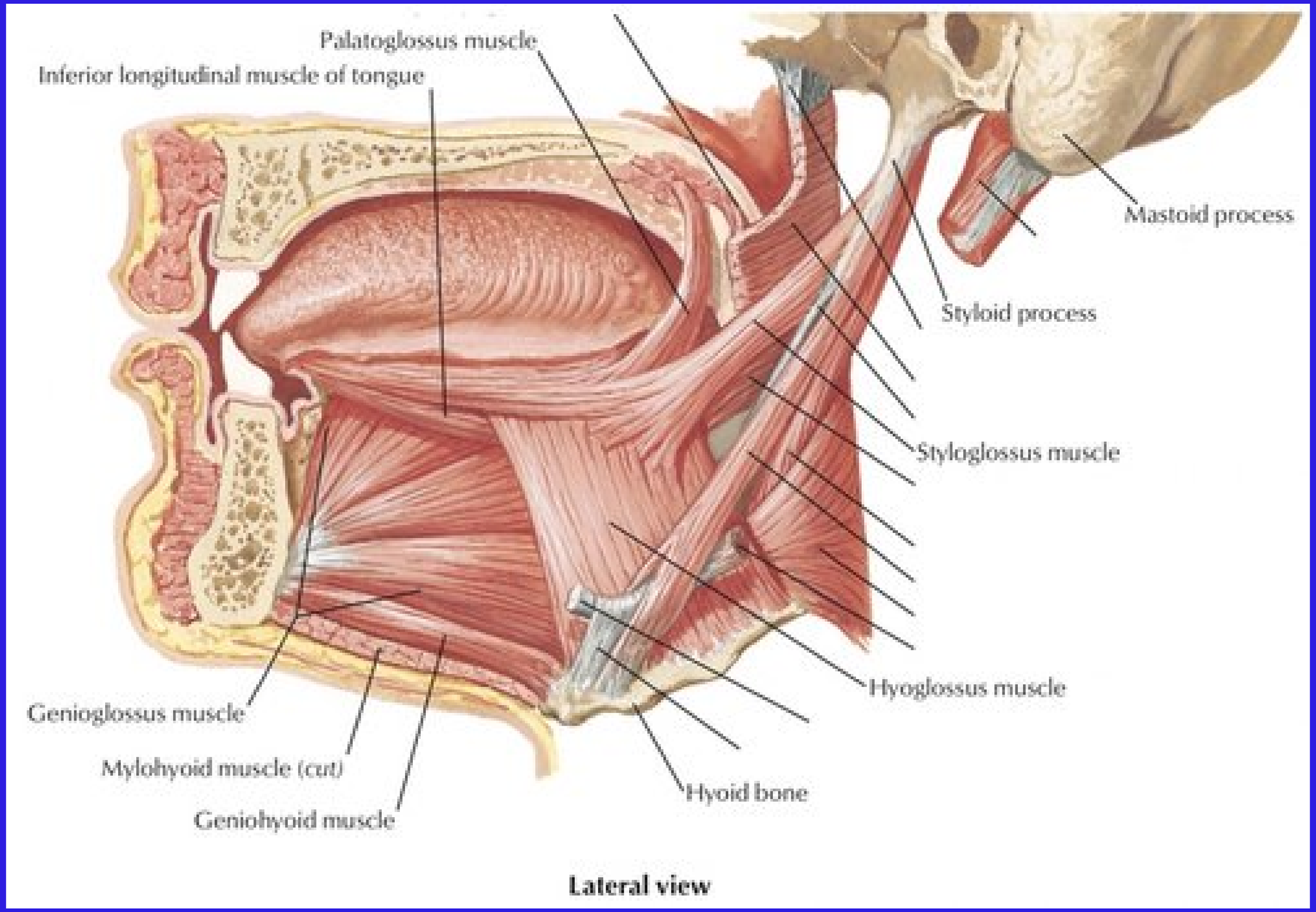
Palatoglossus muscle
Inferior longitudinal muscle of tongue
Mastoid process
Styloid process
Styloglossus muscle
Hyoglossus muscle
Genioglossus muscle
Mylohyoid muscle (cut)
Geniohyoid muscle
Hyoid bone
Lateral view

Role of The Tongue in Swallowing

- manipulate, shape, hold, and then transfer the bolus into the oropharynx,
- signaling the onset of the oral stage of the swallow as the swallowing sequence transitions into the pharyngeal stage
- with the passage of the bolus through the oropharyngeal helps maneuver the food inside the oral cavity
- directs the food onto the occlusal surfaces of the teeth so it can be broken down
- pushes food "out" while cheek pushes food "in"pushes food to the back to initiate swallowing

Quiz Question

WHAT IS THE ROLE OF THE LARYNX IN SWALLOWING?

Larynx

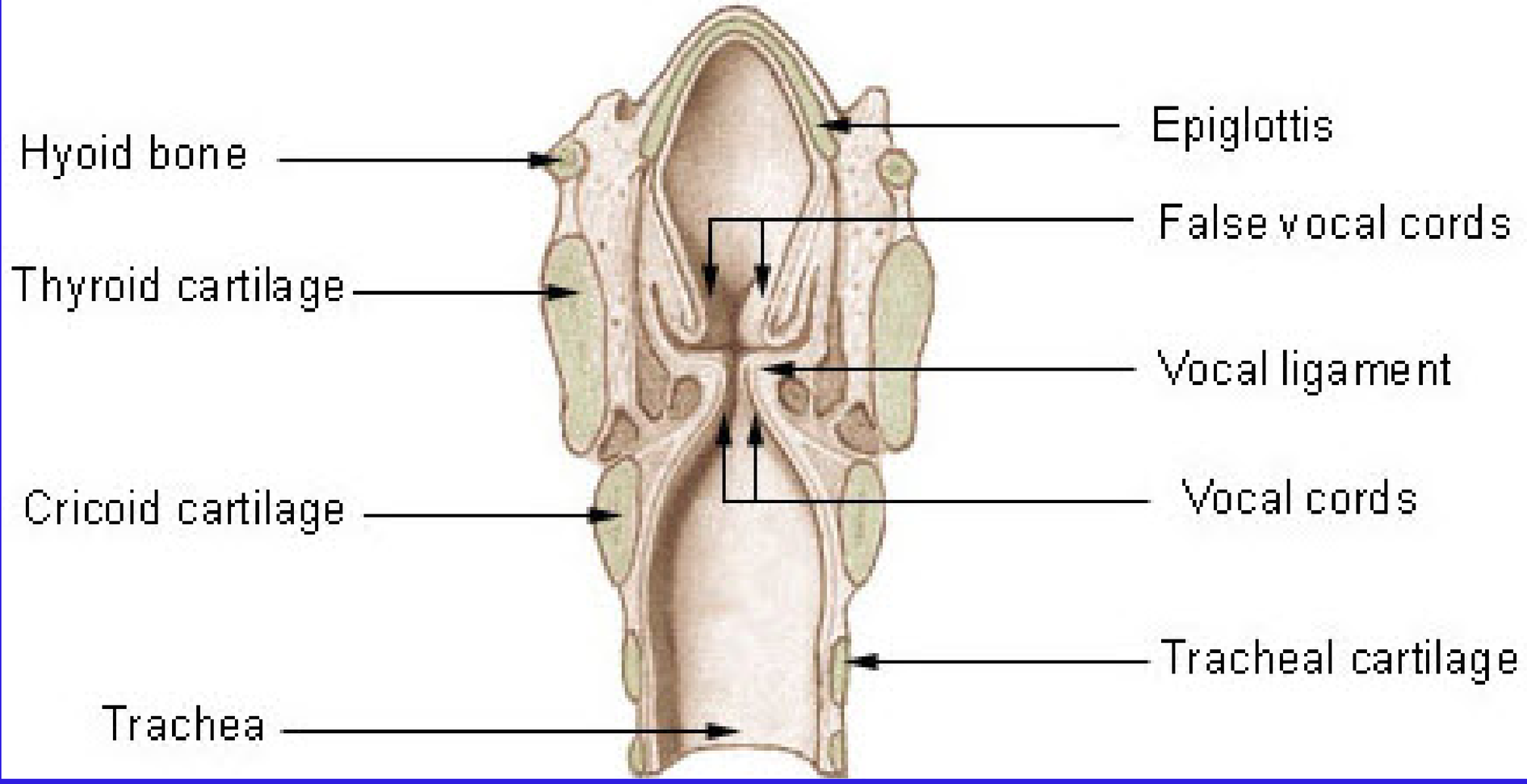
Hyoid bone
Thyroid cartilage
Cricoid cartilage
Trachea
Epiglottis
False vocal cords
Vocal ligament
Vocal cords
Tracheal cartilage

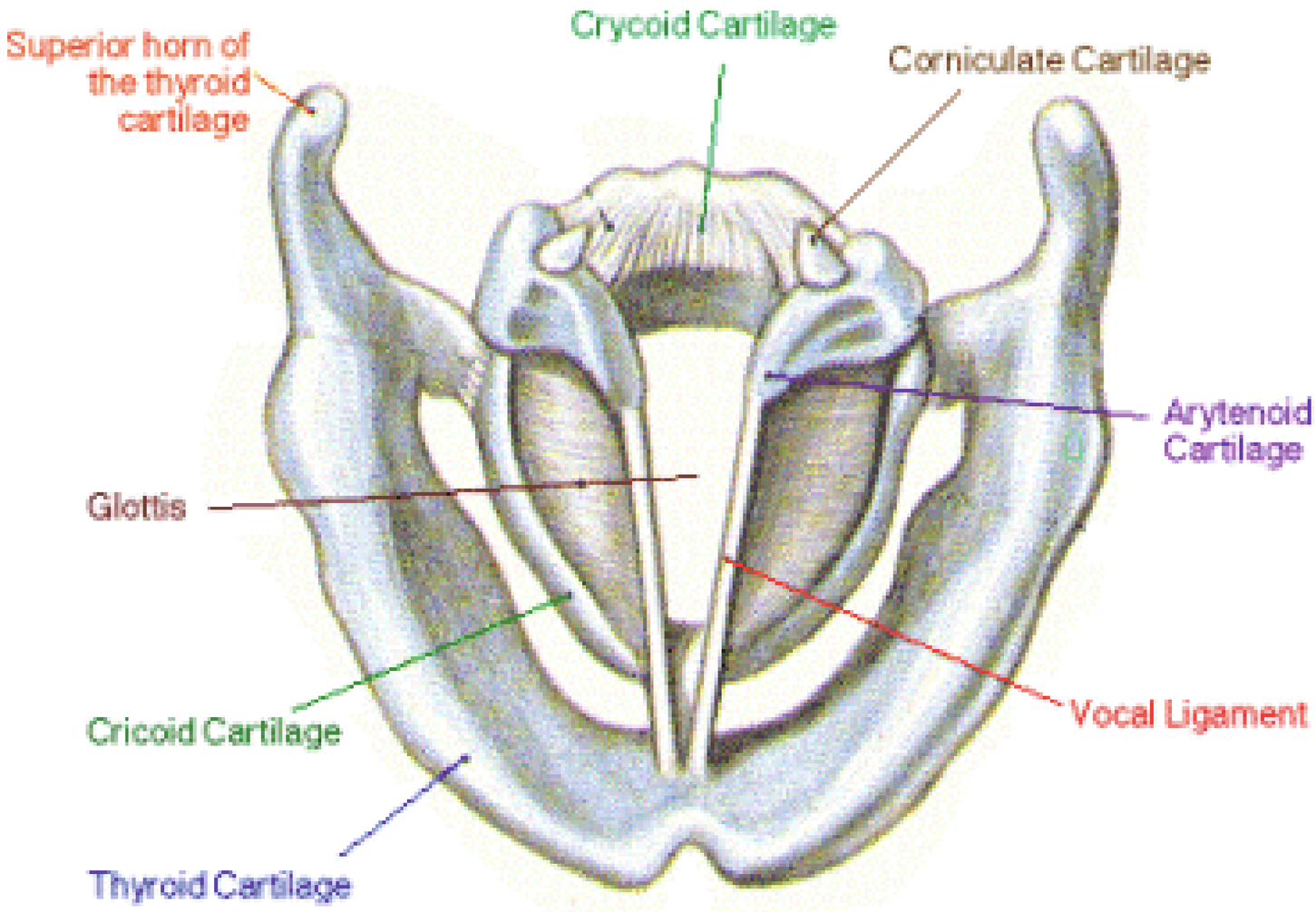

The Larynx: viewed from above

Role of The Larynx in Swallowing

- The larynx is positioned in the front of the neck and serves to separate the respiratory (breathing) and digestive (swallowing) tracts.
- The protective function is entirely reflexive and involuntary, whereas the respiratory and phonatory functions are initiated voluntarily but regulated involuntarily.
-

Phases of The Swallow

Oral

Preparatory

Phase

Phases of The Swallow

Oral Phase

Phases of The Swallow

Pharyngeal Phase

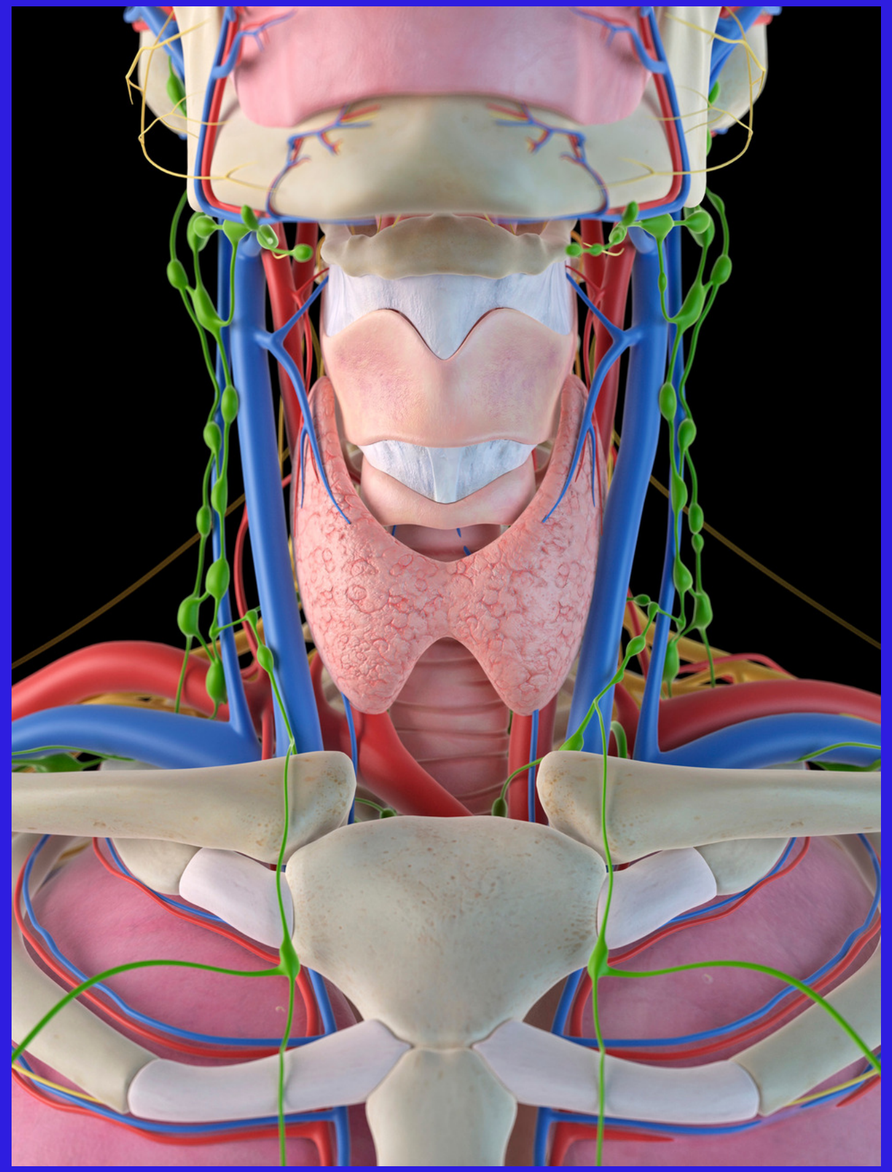

Quiz Question

Which of the following is not a part of the pharyngeal phase of swallowing?

a. Laryngeal elevation
b. Gastroesophageal reflux
c. Multiple swallows of one bolus
d. Penetration of bolus to the level of the false vocal folds

Phases of The Swallow

Esophageal Phase

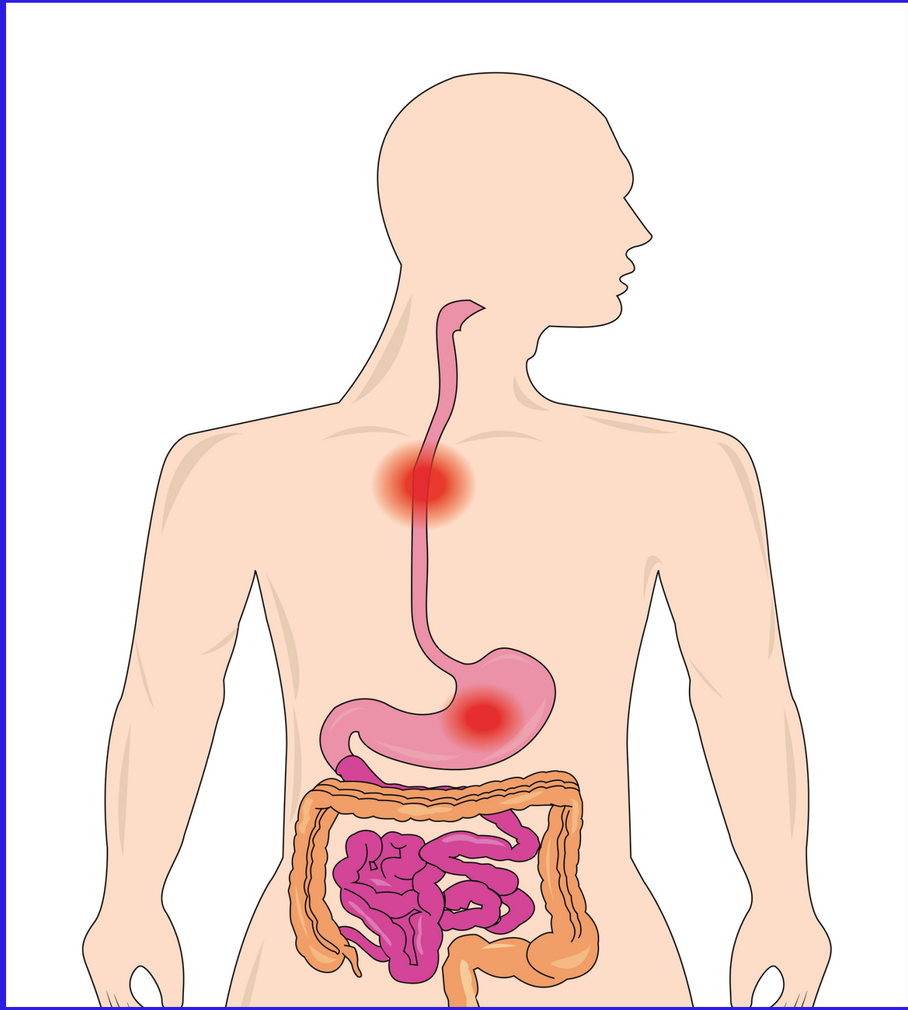

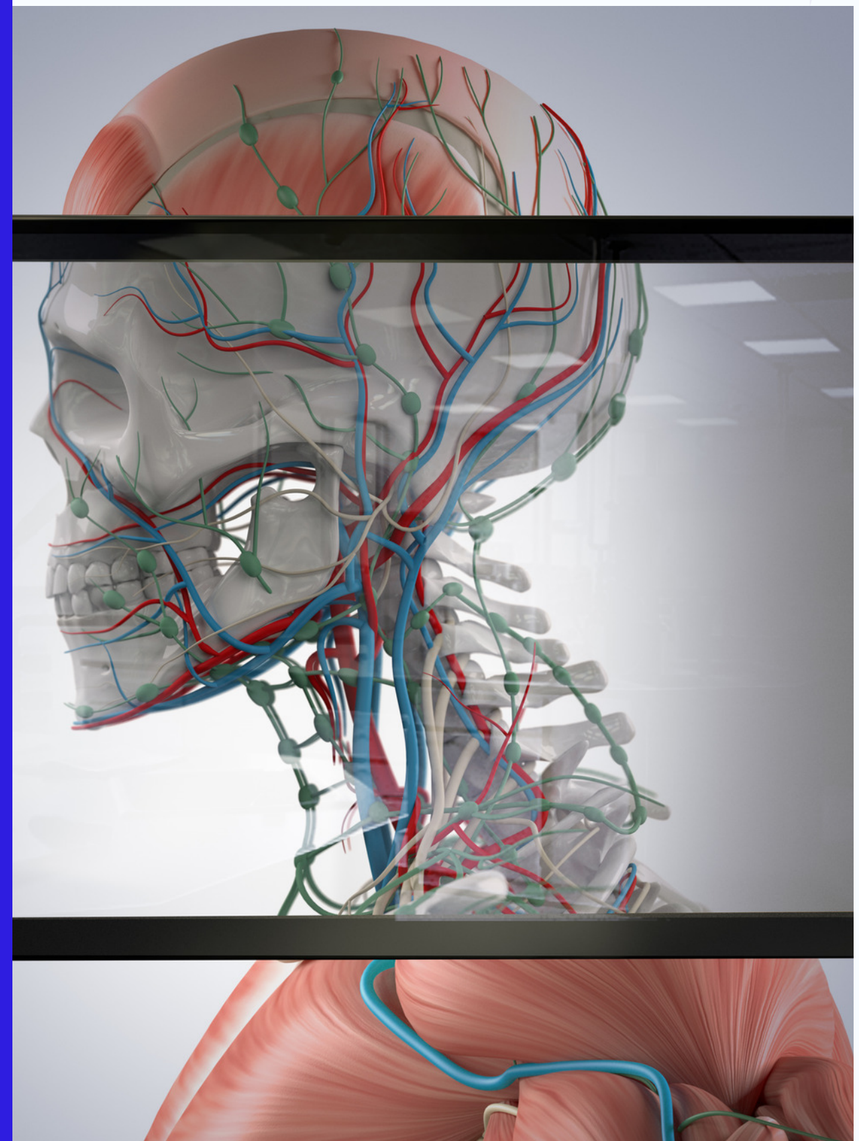

NORMAL SWALLOW

NORMAL SWALLOW

NORMAL SWALLOW VERSUS DYSPHAGIA

PHASES OF THE SWALLOW

Quiz Question

WHAT CRANIAL NERVES ARE INVOLVED IN THE SWALLOWING PROCESS?

THE CRANIAL NERVES AND THE SWALLOW

Cranial nerves are the nerves that emerge directly from the brain. This is in contrast to spinal nerves, which emerge from segments of the spinal cord. Generally, the left side of the brain controls the right side of the body. The right side of the brain controls the left side of the body.

However, when it comes to swallowing, many of these muscles receive bilateral innervation, meaning the brain has a much higher chance of recovering swallow abilities after unilateral brain damage, such as a stroke, or an injury to one side of the head.

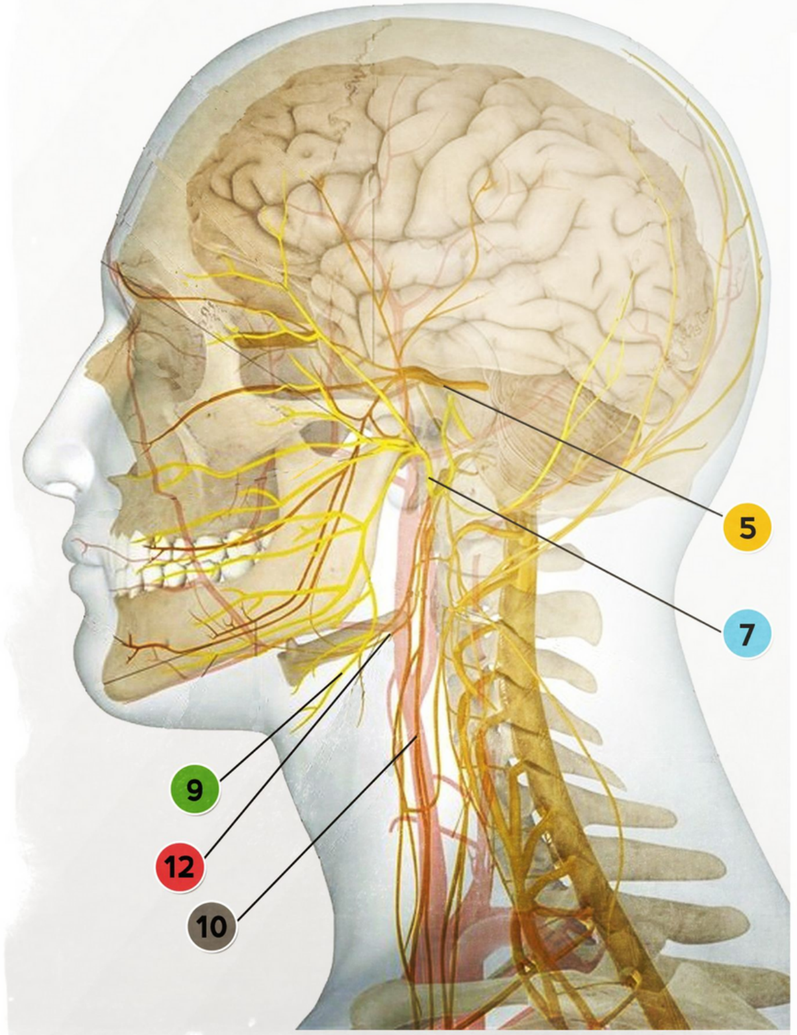

CRANIAL NERVE		IF DAMAGED
5	**TRIGEMINAL NERVE** Controls muscles of biting and chewing; provides sensation to face, cheeks, lips, jaw, forehead, eyes, eyebrows, nose, including pain, temperature, touch, and proprioception. Assists with upward/anterior movement of larynx, backward movement of tongue to soft palate, tensing the soft palate, and posterior pharyngeal wall constriction.	Loss of sensation; inability to move mandible (lower jaw).
7	**FACIAL NERVE** Provides the sense of taste in the front two-thirds of the tongue; controls the muscles of the face, including the circular muscles around the lips that assist with lip closure and keeping food/liquids in the mouth.	Paralysis of facial muscles. Poor lip strength. Dry mouth. Diminished jaw opening/closing. No taste in front 2/3 of tongue.
9	**GLOSSOPHARYNGEAL NERVE** Transmits sensation to the tongue, pharynx, and soft palate (soft part of roof of mouth). Provides sense of taste to back 1/3 of tongue. Related to dry mouth in response to fear and salivation in response to smelling food.	Decreased sense of taste and salivation; diminished or inhibits gag reflex. Weak cough reflex.
10	**VAGUS NERVE** Controls sensation of larynx, base/back of tongue, pharynx, palate, and their muscles.	Difficulty swallowing, nasal regurgitation, reduced or lost gag reflex. Hoarse, breathy, wet, voice. Inability to vary pitch.
12	**HYPOGLOSSAL NERVE** Controls the muscles of the tongue. If damage is to the nerve itself (a lower motor neuron lesion), the tongue will curve toward the damaged side. If the damage is to the nerve pathway (an upper motor neuron lesion) the tongue will curve away from the side of damage, and will occur without fasciculations or wasting, with speech difficulties more evident.	Inability to position food for chewing, resulting in food getting pocketed in cheeks.

Quiz Question

Injury to the motor branch of the vagus nerve results in

a. Inadequate velopharyngeal closure
b. Inadequate vocal fold closure
c. Possible nasal regurgitation
d. Pooling of bolus residue in the hypopharynx
e. All of the above

Dysphagia may result from numerous etiologies:

- Damage to the central nervous system (CNS) and/or cranial nerves, and unilateral cortical and subcortical lesions, due to stroke
- Traumatic brain injury; spinal cord injury
- Dementia
- Parkinson's disease
- Multiple Sclerosis
- ALS (or Lou Gehrig's disease)
- Developmental disabilities in an adult population (i.e., cerebral palsy); and/ormyasthenia gravis.

NEUROLOGICAL ETIOLOGIES

- Stroke
- Dementia
- TBI Traumatic Brain Injury
- Brainstem Tumor
- Parkinson Disease
- Multiple Sclerosis
- Spinal cord injury
- Cerebral Palsy

SWALLOWING AFTER STROKE

- Reduced oral stage management
- Incoordination of oral movements
- Absent/Delayed Pharyngeal response
- Inadequate airway closure
- Reduced hyolaryngeal elevation
- Reduced oropharyngeal constriction
- Aspiration
- Pharyngoesophageal segment dysfunction

SWALLOWING IN DEMENTIA

- Unexplained Weight Loss
- Oral-Stage dysfunction
- Pharyngeal phase dysfunction
- Feeding limitations
- Slow oral movements
- Delayed pharyngeal response
- Pharyngeal weakness

SWALLOWING IN PARKINSON'S

ORAL STAGE

- Lingual tremor
- Repetitive tongue pumping
- Piecemeal deglutition
- Velar tremor
- Buccal rention (pocketing)

SWALLOWING IN PARKINSON'S

PHARYNGEAL STAGE

- Vallecular retention
- Piriform sinus retention
- Impaired laryngeal elevation
  - Commonly occuring
- Airway penetration (supraglottic)
- Aspiration

OTHER ETIOLOGIES & DIAGNOSIS

Dysphagia may also occur from problems affecting the head and neck, including:

- cancer in the oral cavity, pharynx, nasopharynx, or esophagus;
- chemoradiation for head and neck cancer treatment;
- trauma or surgery involving the head and neck;
- critical care that may have included oral intubation and/or tracheostomy;
- certain medications;
- patients with a variety of pulmonary diseases (e.g., cardiac obstructive pulmonary disease [COPD]);
- Decompensated elderly patients.

IATROGENIC DIAGNOSES

- Radiation Therapy
- Chemotherapy
- Intubation or Tracheostomy
- Postsurgical cervical spine fusion
- Medication related
  - CNS suppressing drugs

OTHER DIAGNOSES

- Severe Respiratory Compromise
  - COPD
  - Intubation
- Psychogenic Disorders
- Structural Diagnosis
  - Tumors
  - Nodules
- Age Related Weakness

RESPIRATORY COMPROMISE

- Poor coordination of the swallow.
- Reduced airway closure
- Inability to time cough
- Reduced laryngeal elevation
- Increased scar tissue
- Increased Fatigue
- Muscle weakness

AGE RELATED DEFICITS

- Increased Fatigue
- Muscle weakness
- Reduced muscle tone
- Reduced sensation and sensitivity
- Reduced sensory abilities (taste, smell...)
- Reduced movement of tongue
- Buccal Retention
- Dentition Deficits

INCIDENCE & PREVALENCE

Dysphagia

ASHA Estimates that each year, approximately one in 25 adults will experience a swallowing problem in the United States (Bhattacharyya, 2014). Dysphagia cuts across so many diseases and age groups, its true prevalence in adult populations is not fully known and is often underestimated.

Dysphagia in adults is often a secondary diagnosis resulting from a primary diagnosis such as stroke, head injury, or cancer.

SIGNS & SYMPTOMS

SYMPTOMS OF DYSPHAGIA

Difficulty Chewing
Drooling
Difficulty Initiating Swallow
Nasal Regurgitation
Swallow Delay
Food Sticking
Coughing and Choking
Coughing when not eating
Regurgitation
Weight Loss

WHAT'S A SIGN OF EACH?

WHAT'S THE ROLE OF THE SLP?

- Identifying the signs and symptoms of dysphagia
- Identifying normal and abnormal swallowing anatomy and physiology
- Identifying indications and contraindications specific to each patient for various non-instrumental and instrumental assessment procedures.
- Identifying signs of potential disorders in the upper aerodigestive tract and making referrals to appropriate medical personnel.
- Performing, analyzing, and integrating information from non-instrumental and instrumental assessments of swallow function collaboratively with medical professionals.
- Providing safe and effective treatment for swallowing disorders, documenting progress, and determining appropriate dismissal criteria

ASSESSMENT OF SWALLOWING DISORDER

- Swallowing assessment allows the SLP to integrate information from:
- (a) the interview/case history,
- (b) medical/clinical records including the potential impact of medications,
- (c) the physical examination,
- (d) previous screening and assessments, and
- (e) collaboration with physicians and other caregivers.

During assessment, SLPs determine whether the patient is an appropriate candidate for treatment and/or management; this determination is based on findings that include medical stability, cognitive status, nutritional status, and psychosocial, environmental, and behavioral factors.

Assessment Factors

- Non-Instrumental Assessment
  - Examination of cognitive status
  - Structural Assessment/Cranial Nerve Assessment
  - Bedside Swallow Examination
  - Cough Strength Assessment
  - Consider respiratory/swallow rate
- Instrumental Assessment
  - MBSS
  - FEES
  - Needed when Inconsistent signs/symptoms persist
  - Assessment of swallow function beyond the eye and palpation.
  - Rule out silent aspiration
    - Occurs in more than 40% of patients

TREATMENT OF SWALLOWING DISORDER

Treatment & Intervention

- Direct treatment/compensatory strategies
  - Addresses stage specific deficits.
  - Lingual Sweep (oral)
  - Chin Tuck (pharyngeal)
- Oral motor exercises
  - Tongue strengthening with tongue depressor resistance.
- Swallowing maneuvers
  - Effortful Swallow
  - Masako Maneuver
  - Lollipop
- Neuromuscular rehabilitation
  - NMES
- Referral for further Medical treatment
- QUESTIONS ABOUT TREATMENT???

Quiz Question

A videofluoroscopic study of a client with dysphagia revealed pooling of liquids in the valleculae. Which of the following is the most likely overt symptom the client will experience?

a. Watery eyes during swallowing
b. Buccal Retention (pocketing)
c. Neuralgia
d. Esophageal Reflux
e. All of the above

Answer

The valleculae are depressions that lie lateral to the median epiglottal folds. Pooling of the liquids in the valleculae gives a person the feeling that there is material remaining in the respiratory pathway, so coughing would be a natural reaction to expect in this case.

Neuralgia or nerve pain is rarely associated with dysphagia and the other answers are incorrect because they address symptoms related to dysphagia that are not a direct result of pooling of liquids in the valleculae.

Quiz & Answer Session